

DELTA CARE WOUND PROGRAM

MANAGING WOUNDS IN HOSPICE

TOCCARA JULE

RN, BSN, MBA, CHPN, CPHQ, CWOCN, CSSGB
NATIONAL NURSING EDUCATION DIRECTOR


CREATED FOR KENTUCKY HOSPICE
NETWORK

AGENDA

1. Common Hospice Wounds
2. Wound Assessment and Documentation
3. Skin Breakdown Prevention
4. Signs and Symptoms of Infection
5. Managing Wound Infections in Hospice
6. Case Examples

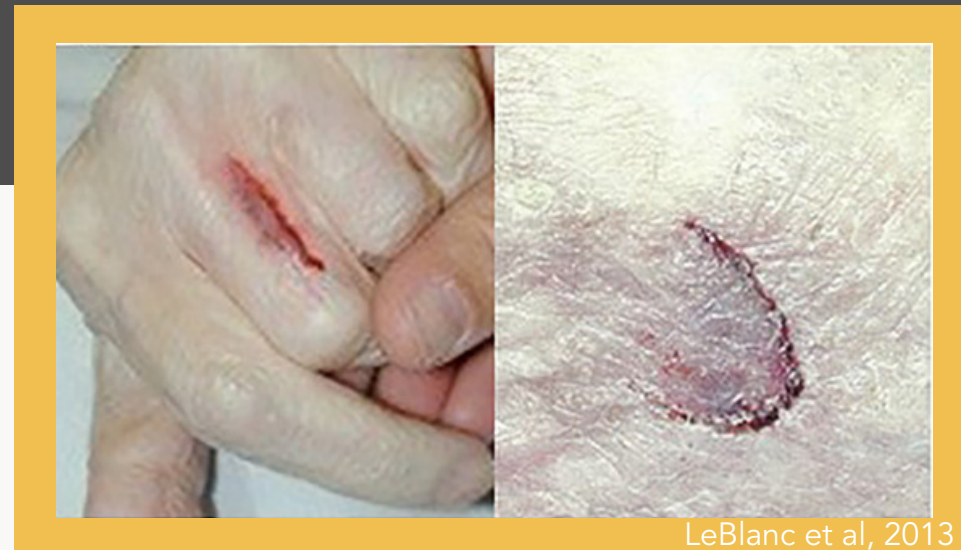1

COMMON HOSPICE WOUNDS



SKIN TEARS

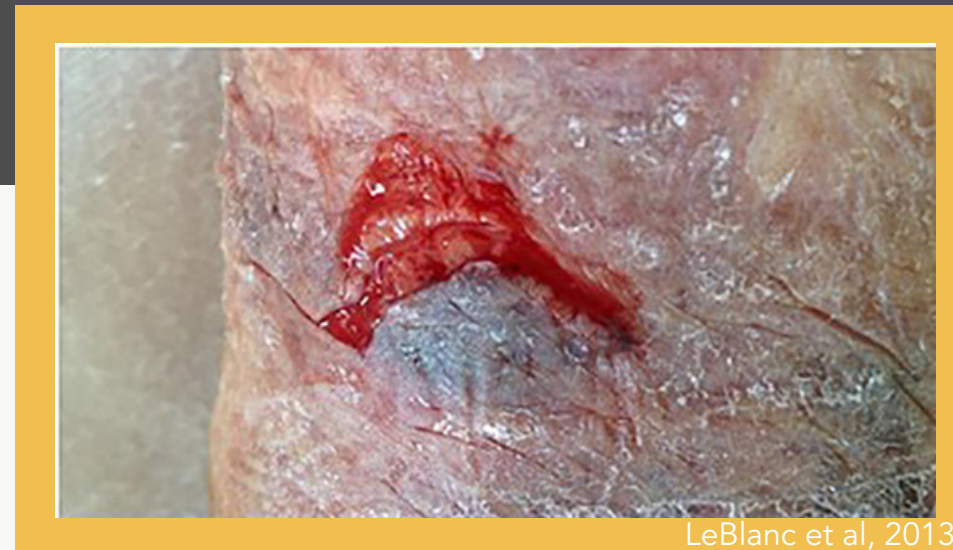TYPE 1



NO SKIN LOSS

Presents as a linear or flap tear that **can be fully reapproximated**

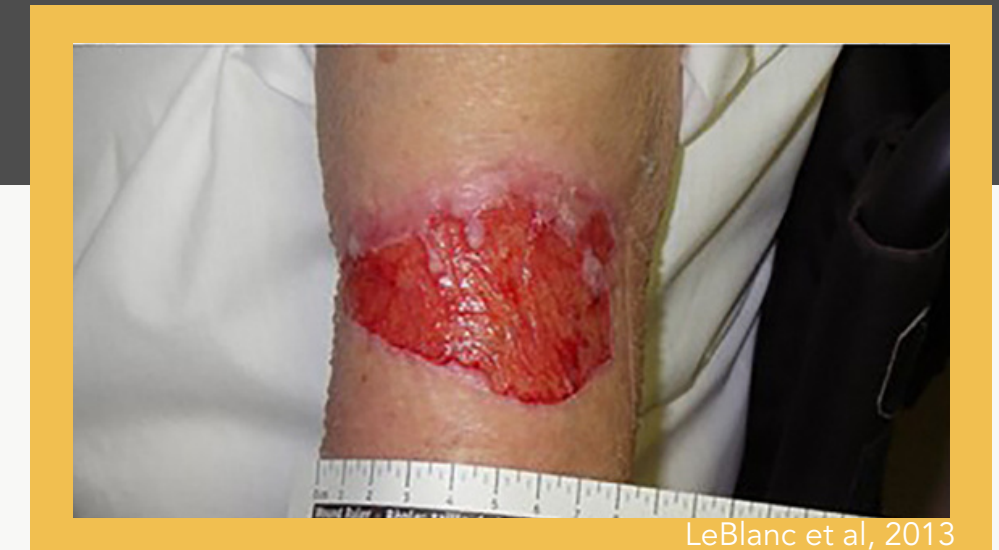TYPE 2



PARTIAL FLAP LOSS

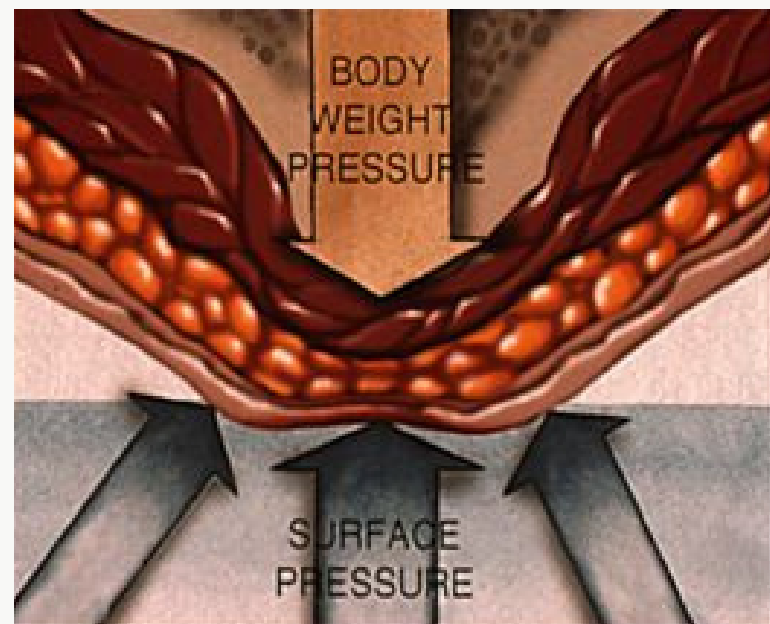
Edges or flap **cannot be fully reapproximated**

TYPE 3



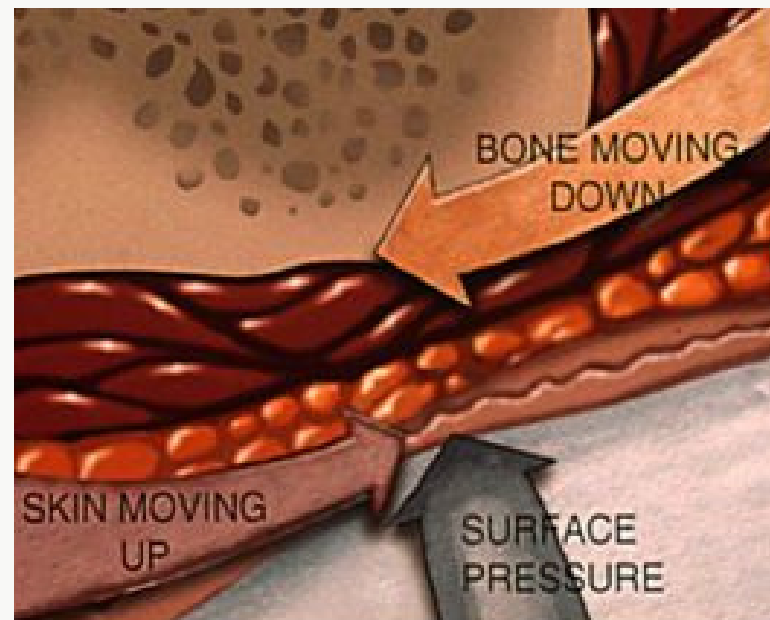
TOTAL FLAP LOSS

Total flap loss; entire wound bed is exposed



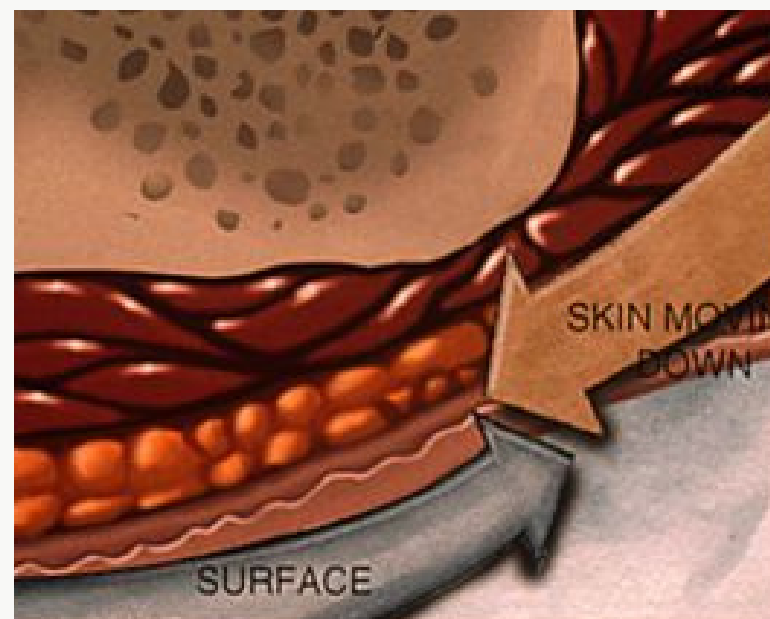
PRESSURE

Squeezing of soft tissues caused by weight



SHEAR

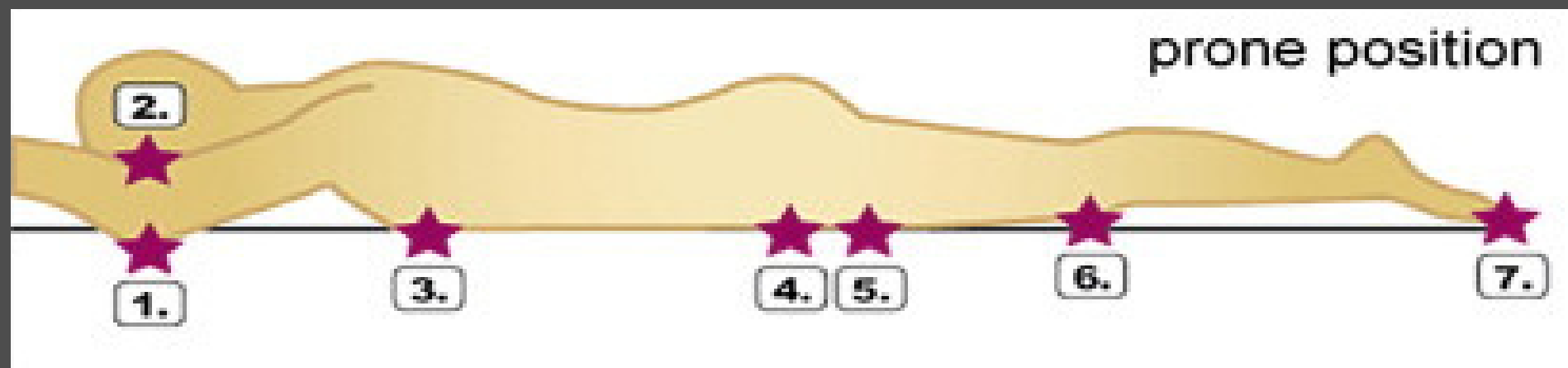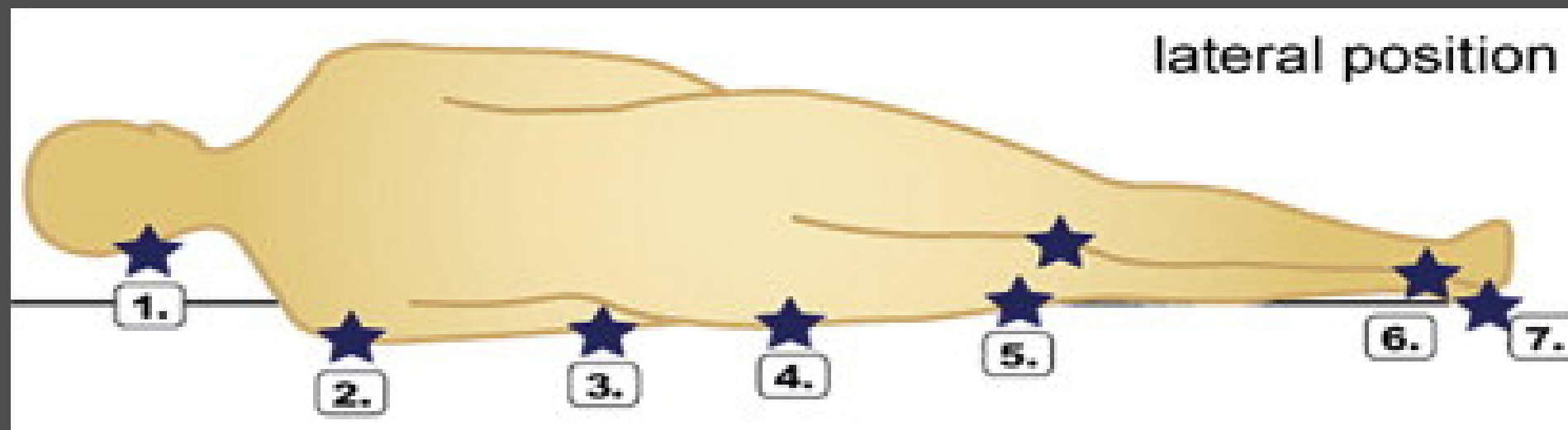
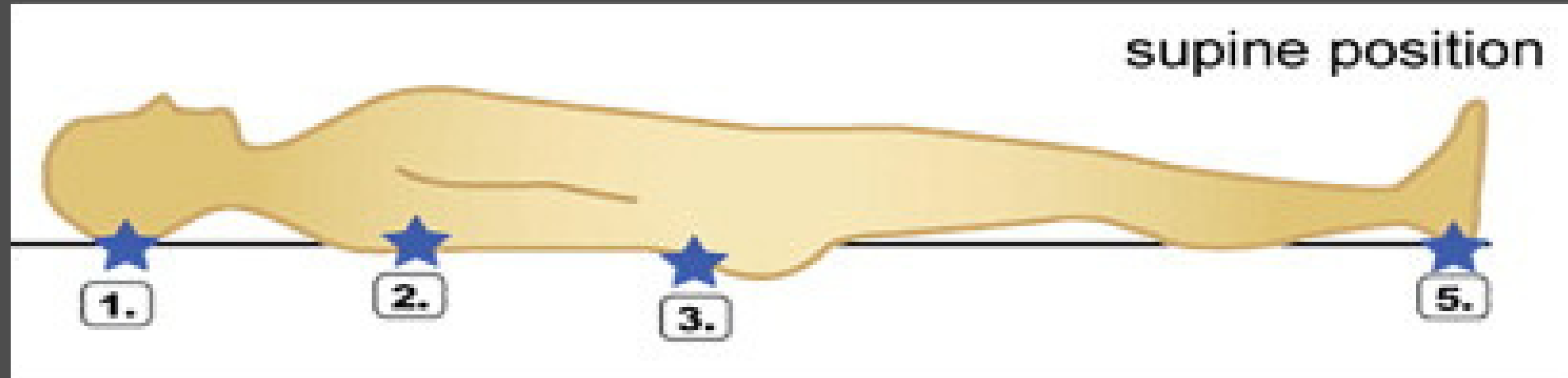
Mechanical force that acts on an area of skin in a direction parallel to the body's surface



FRICTION

Mechanical force exerted when the skin is dragged across a coarse surface

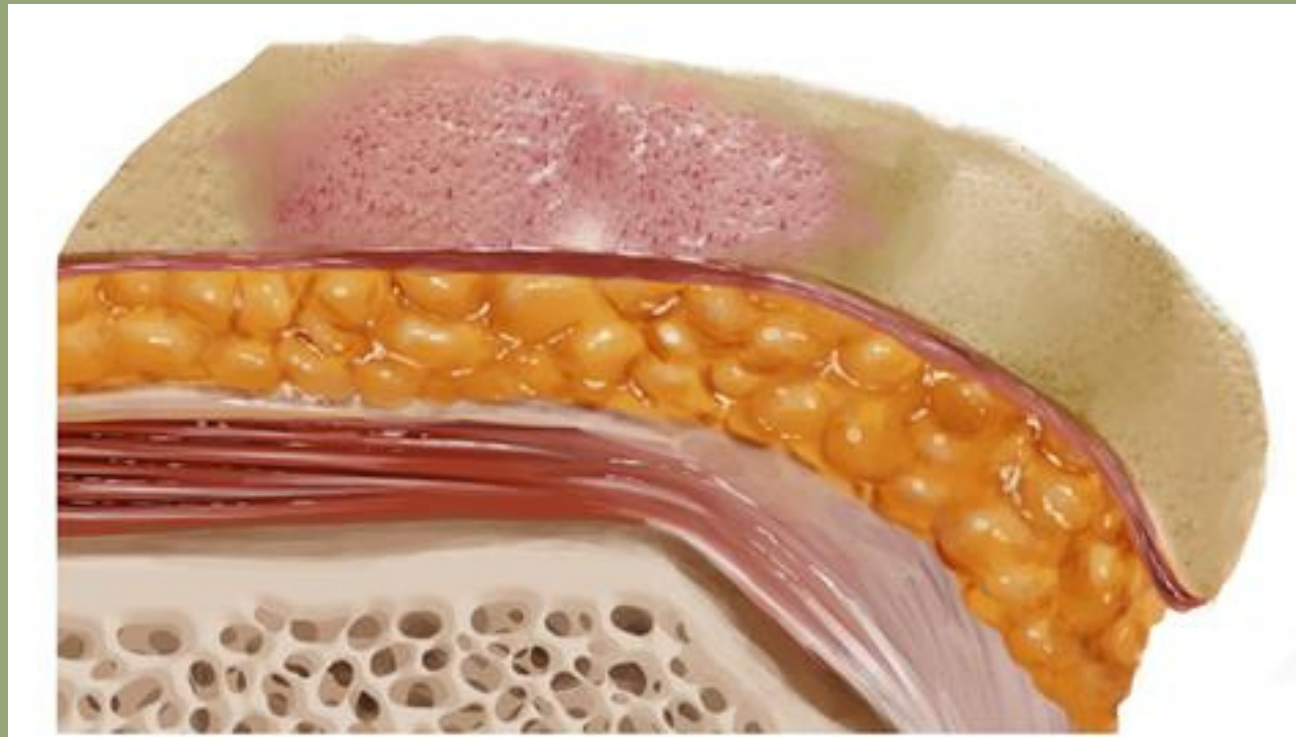
PRESSURE ULCERS



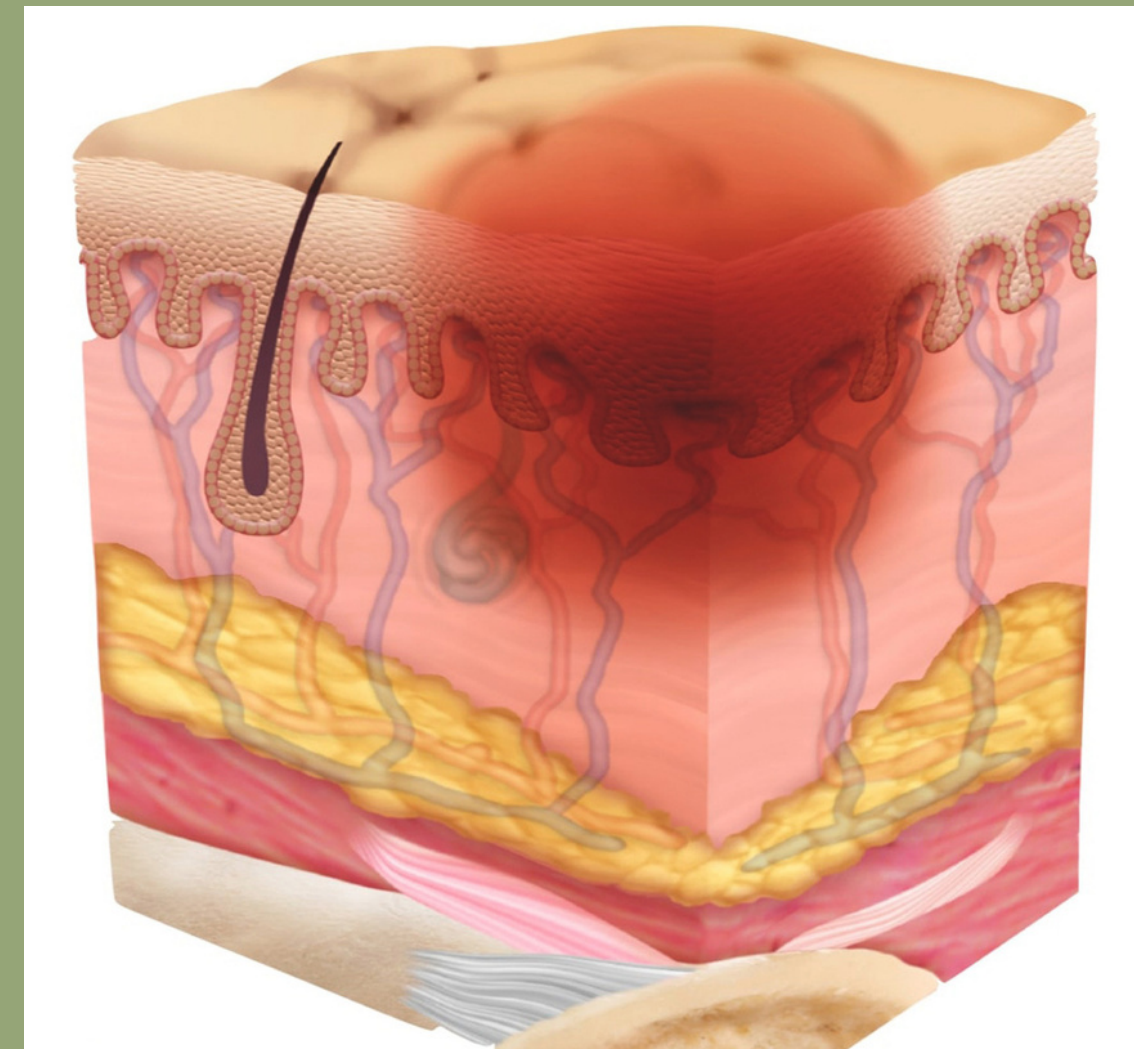
Definition from NPIAP:

A pressure injury is localized damage to the skin and underlying soft tissue usually over a bony prominence or related to a medical or other device. The injury can present as intact skin or an open ulcer and may be painful. The injury occurs as a result of intense and/or prolonged pressure or pressure in combination with shear. The tolerance of soft tissue for pressure and shear may also be affected by microclimate, nutrition, perfusion, co-morbidities and condition of the soft tissue.

PRESSURE ULCER STAGE 1

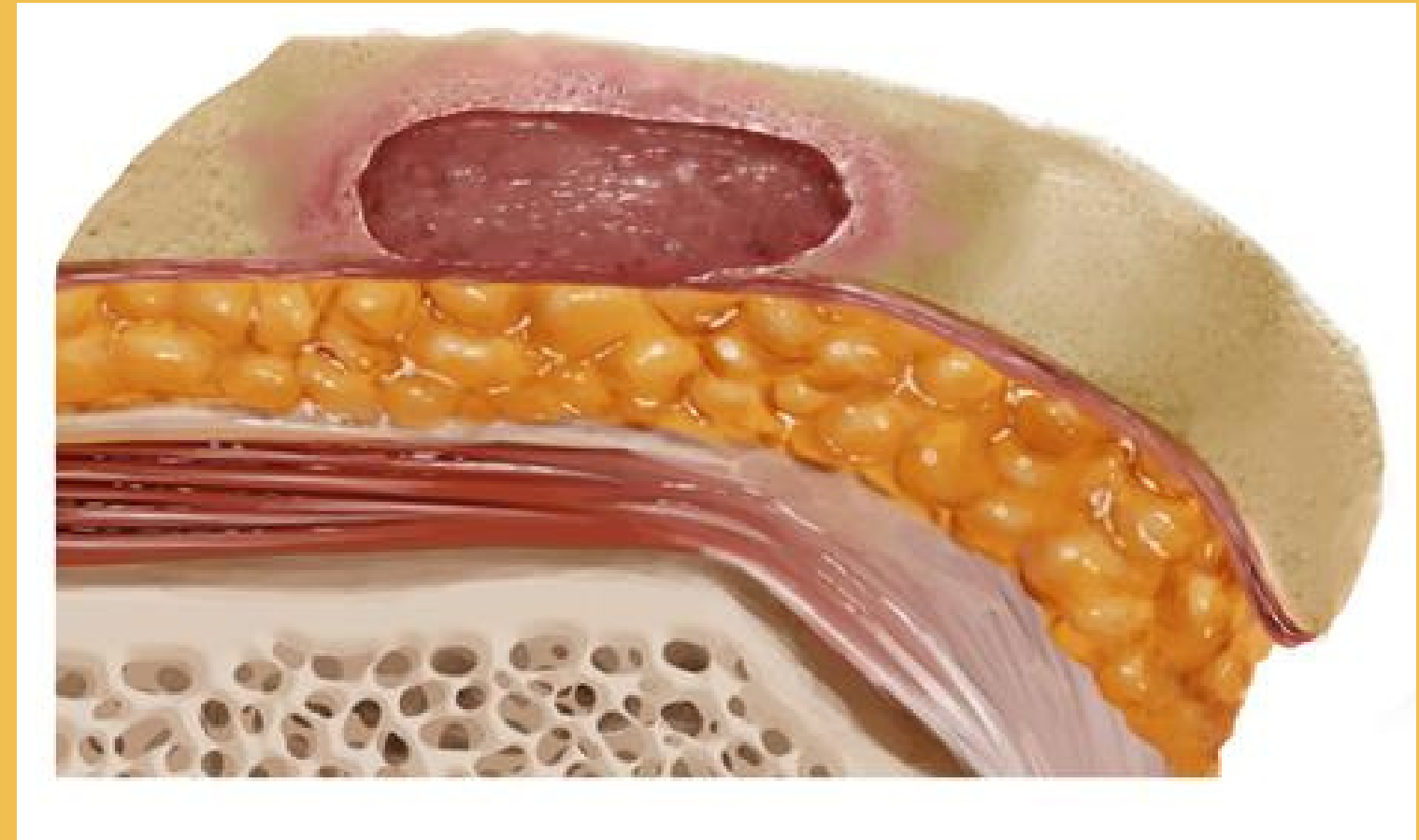
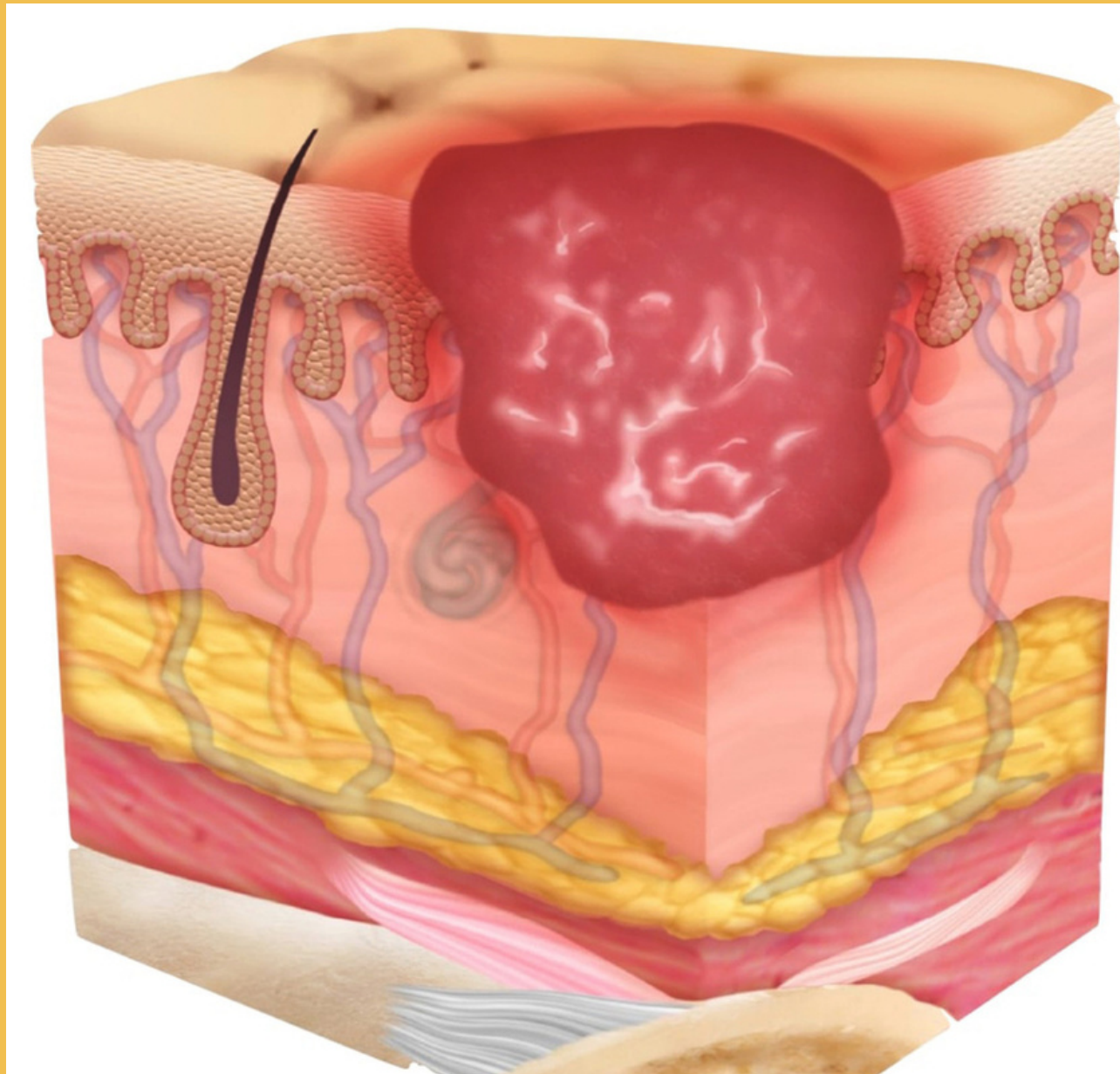


Lineage, n.d.



**Area of non-blanchable redness,
often over a bony prominence**

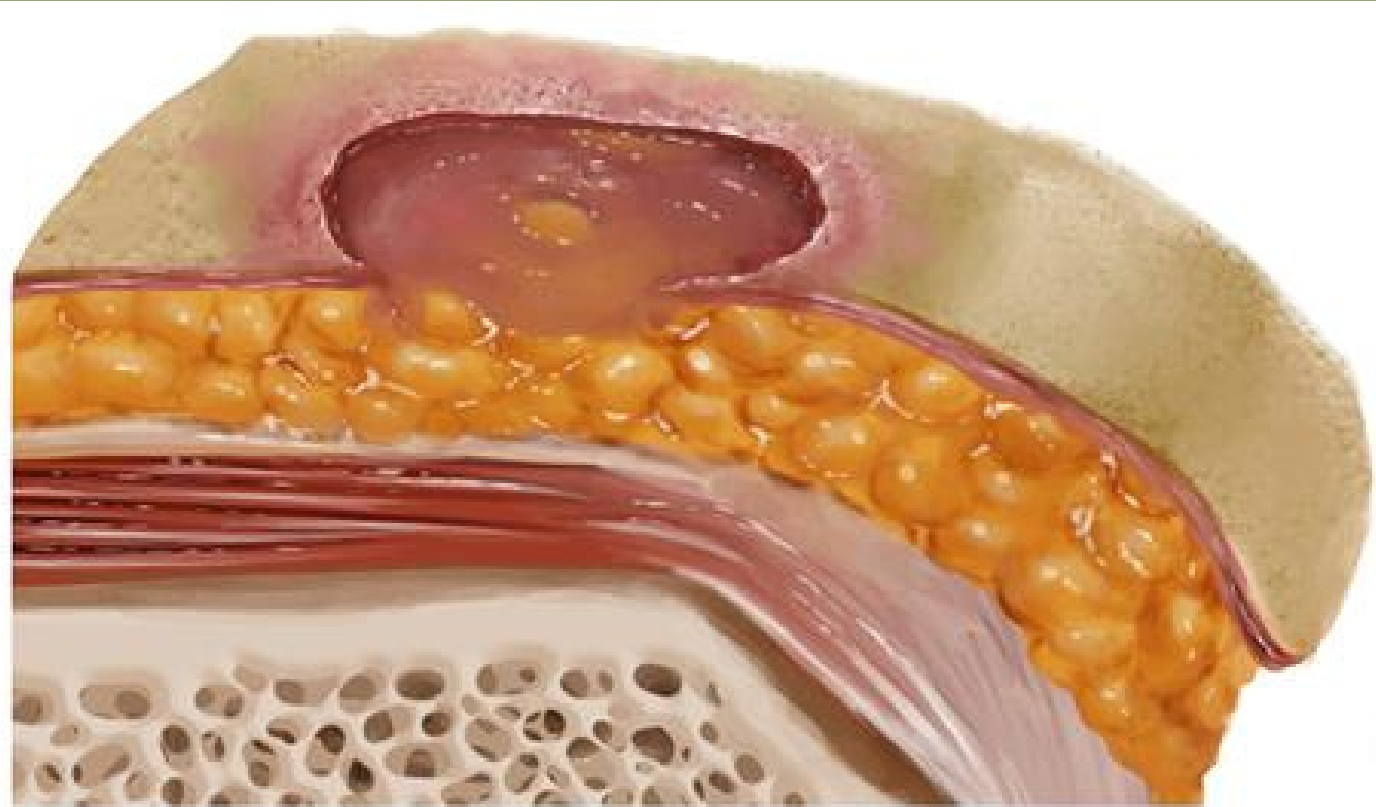
PRESSURE ULCER STAGE 2



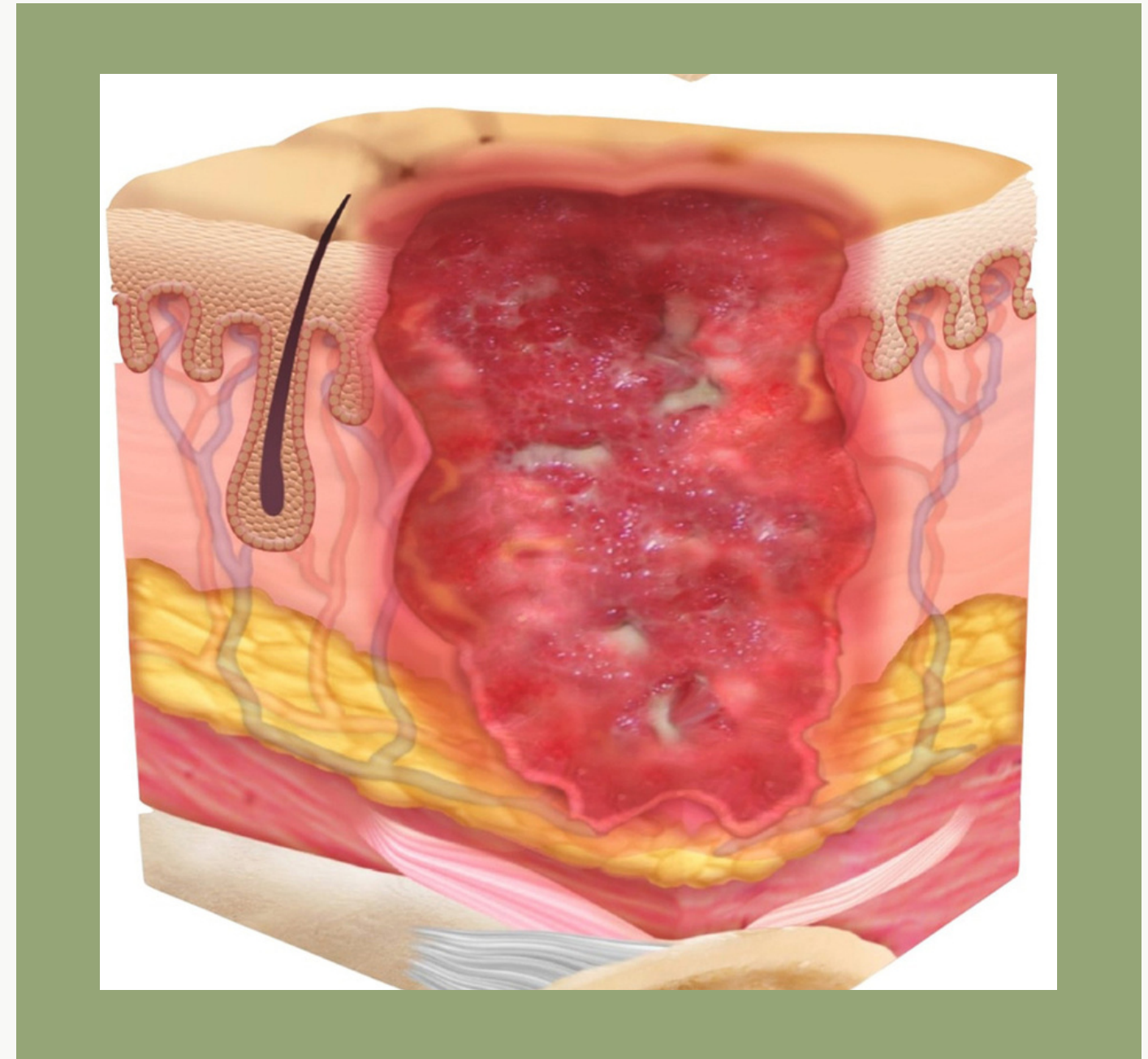
Lineage, n.d.

Serum filled blister or loss of dermis resulting in a shallow ulcer

PRESSURE ULCER STAGE 3

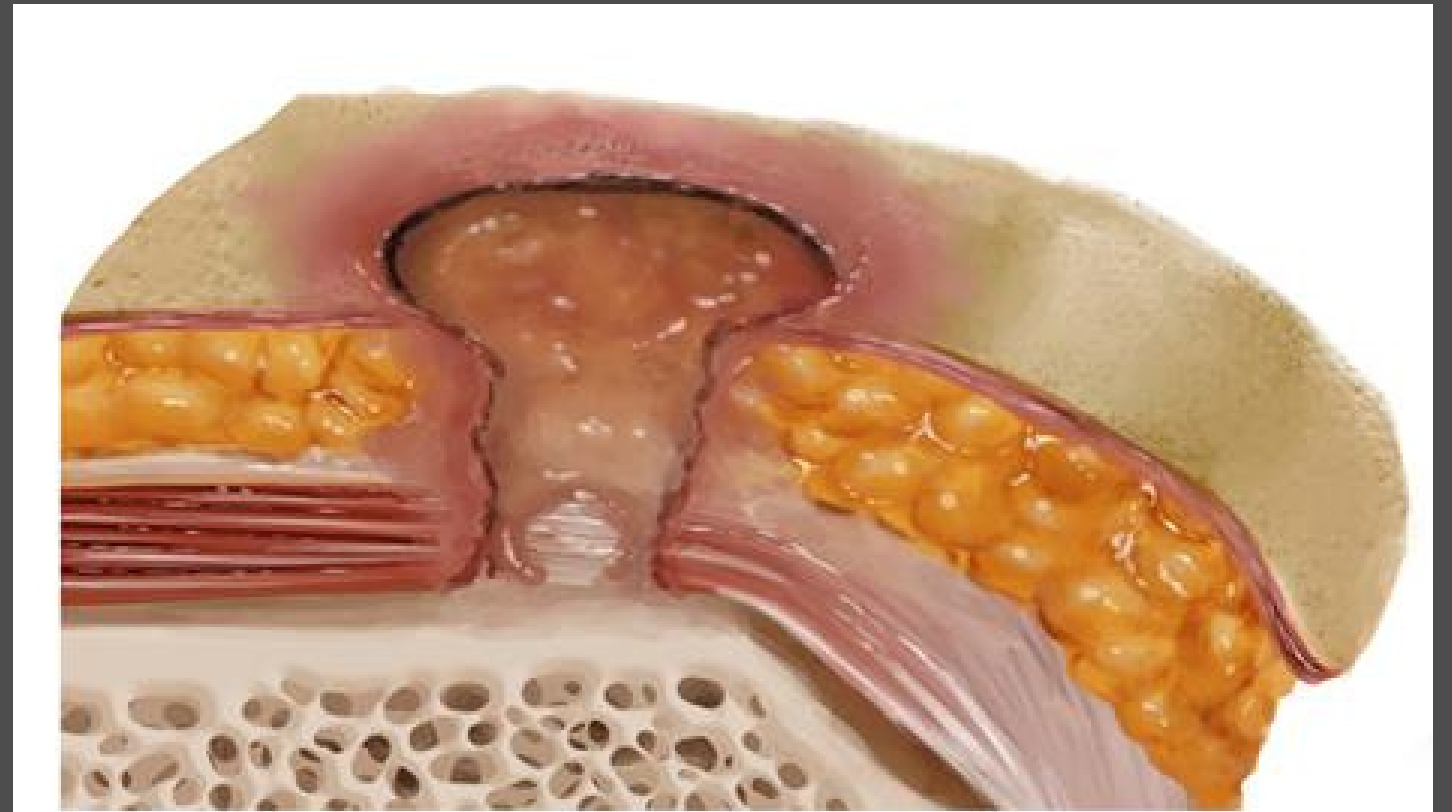
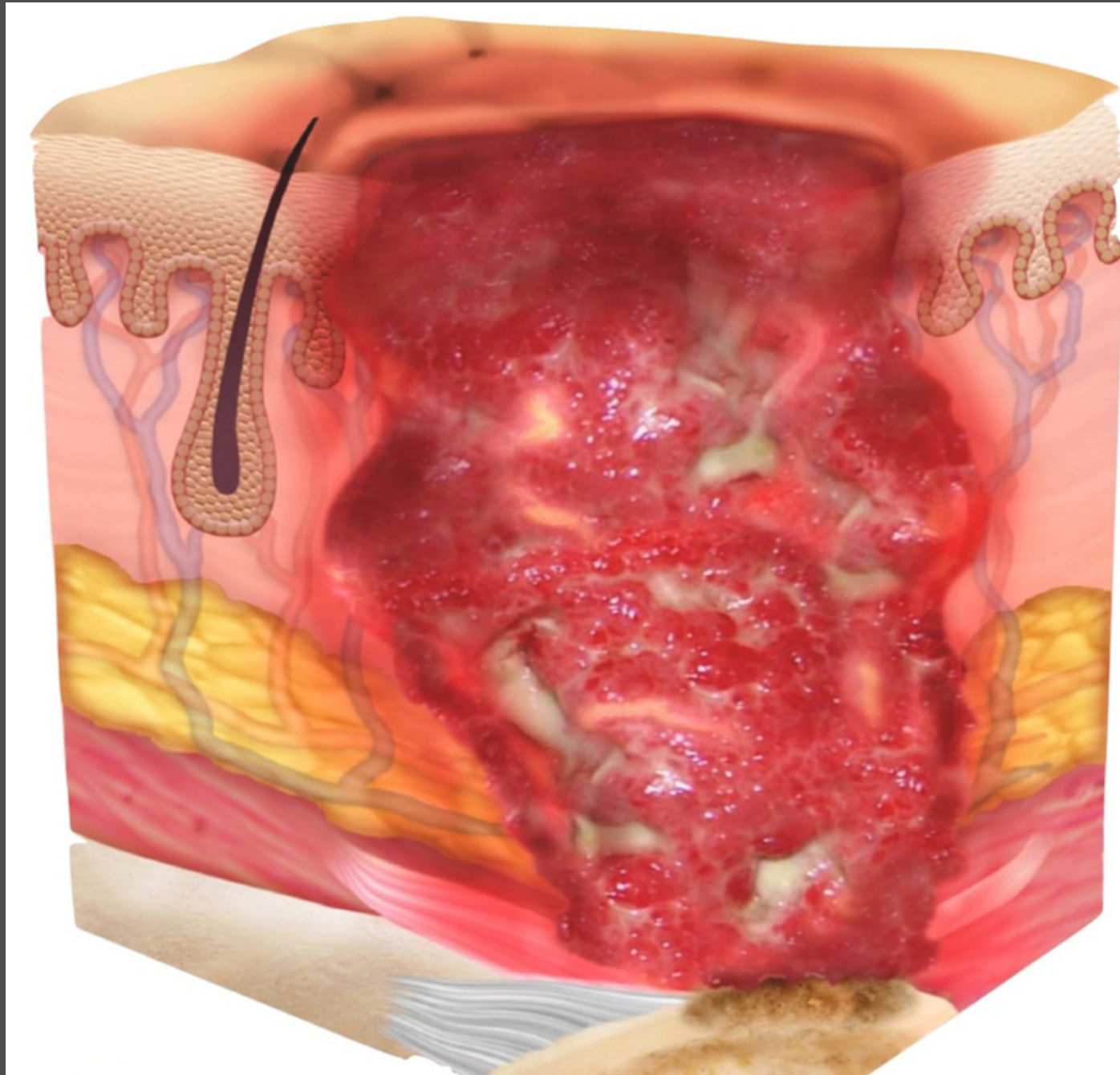


Lineage, n.d.



Ulcer extends beyond dermis into subcutaneous tissue

PRESSURE ULCER STAGE 4

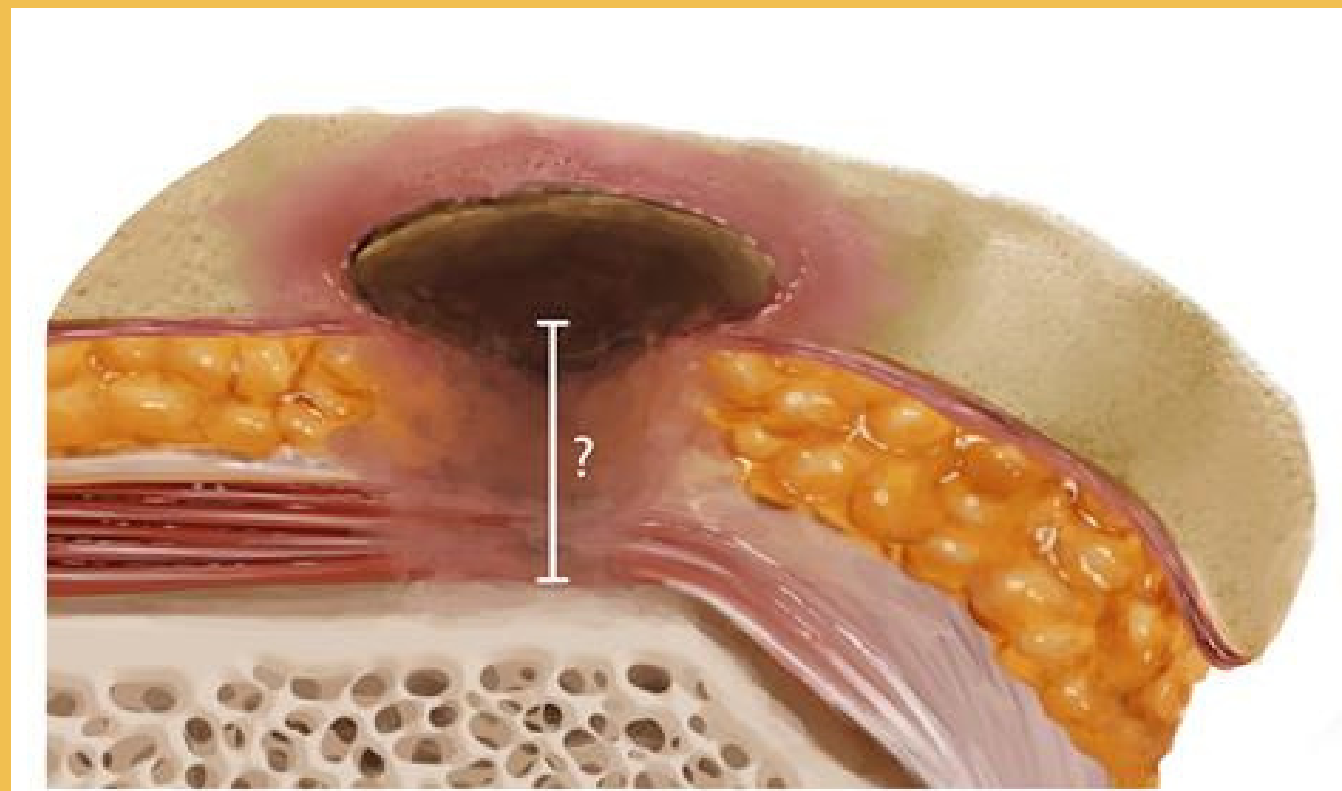


Lineage, n.d.

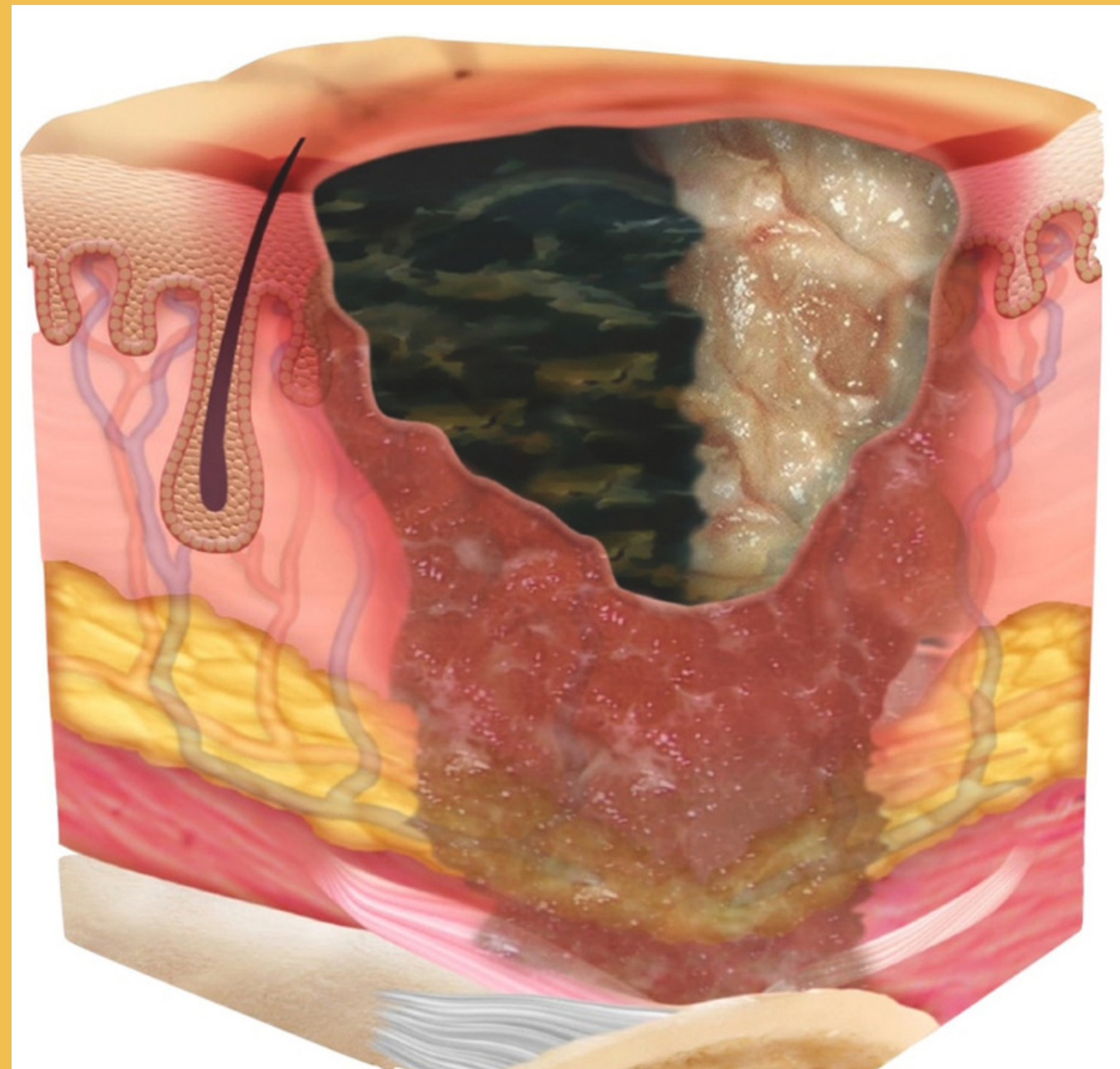
Ulcer has exposed bone,
tendon or muscle

UNSTAGEABLE

Unable to assess wound depth as base of wound obscured by non-viable tissue

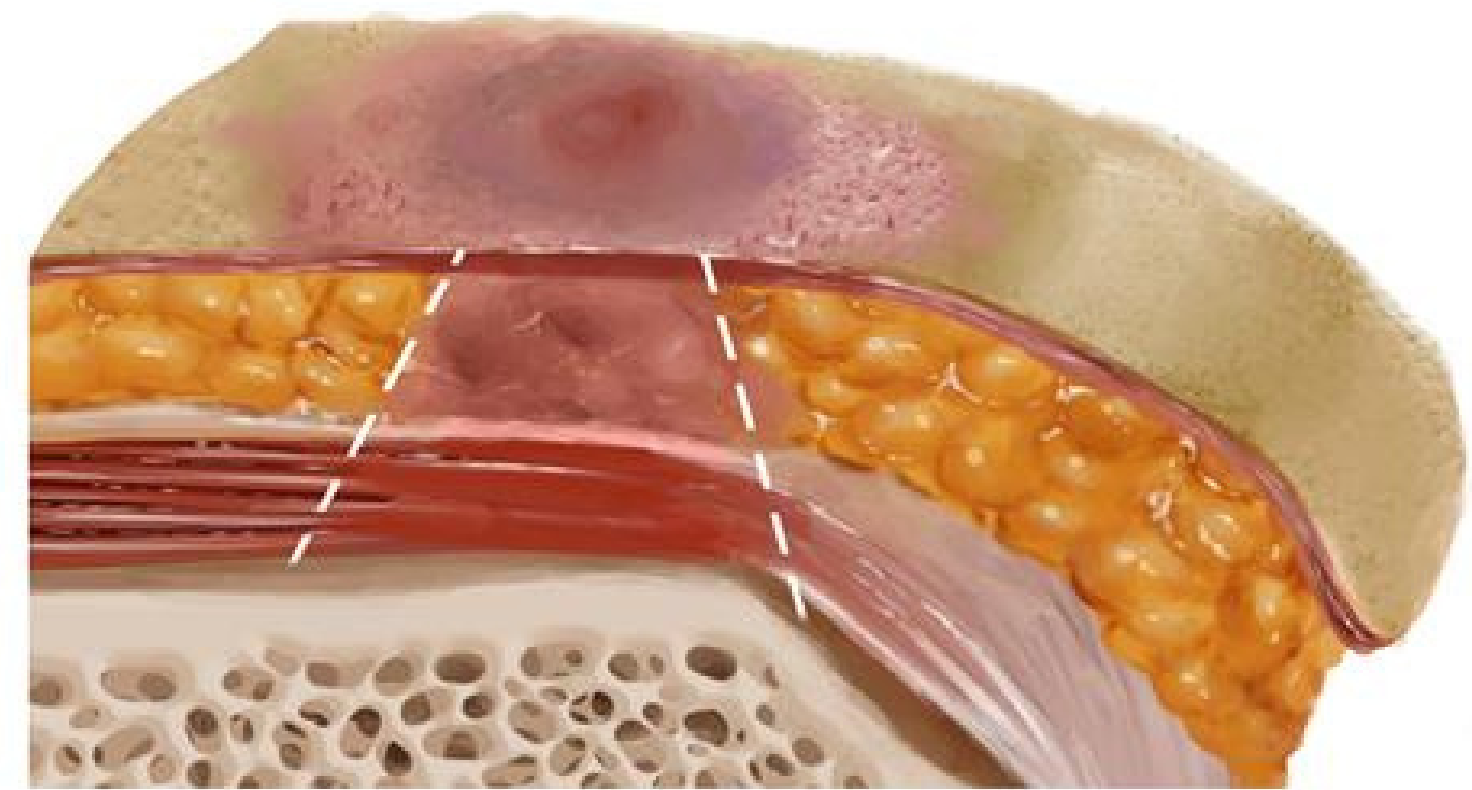
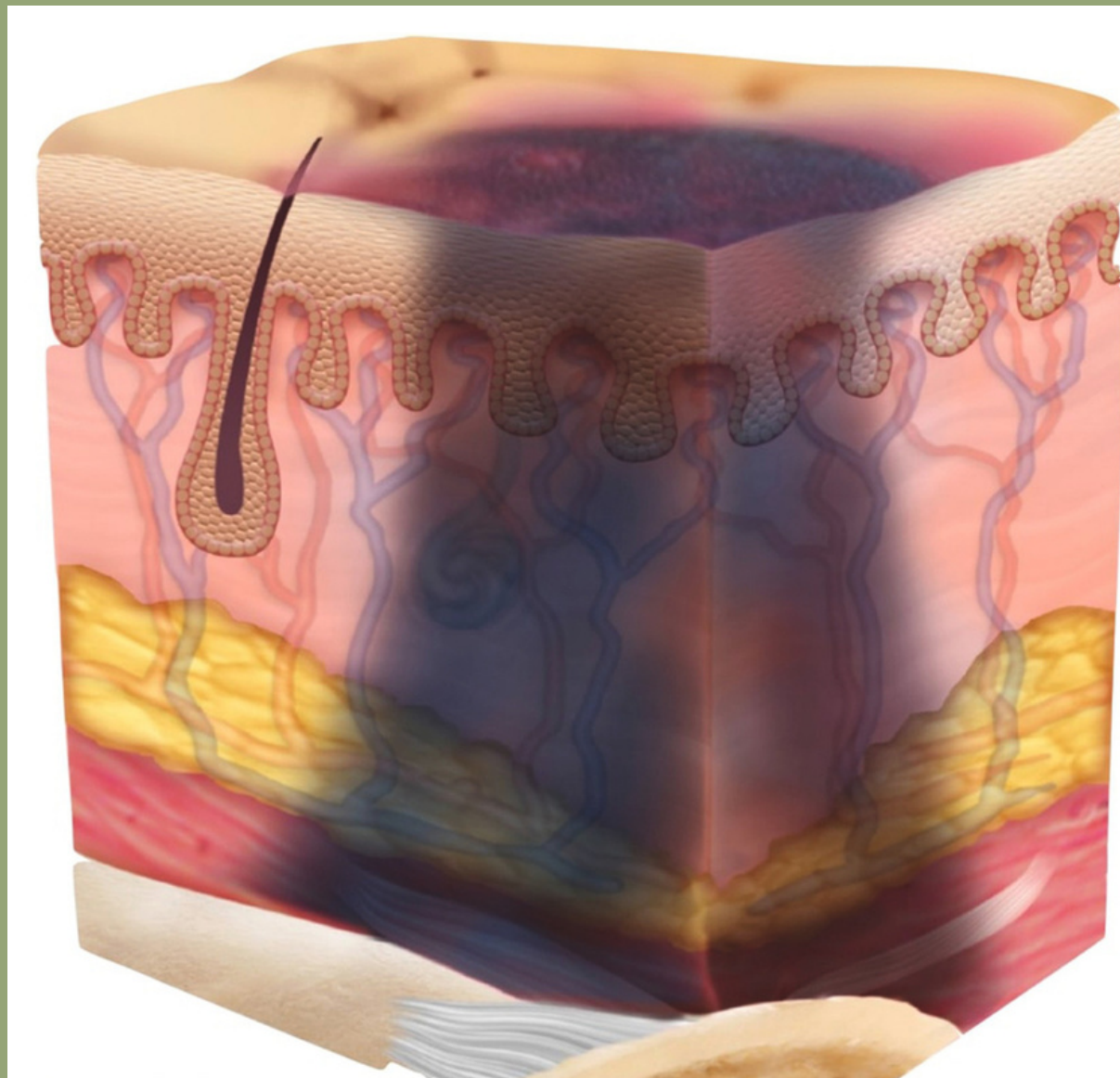


Lineage, n.d.



DTI

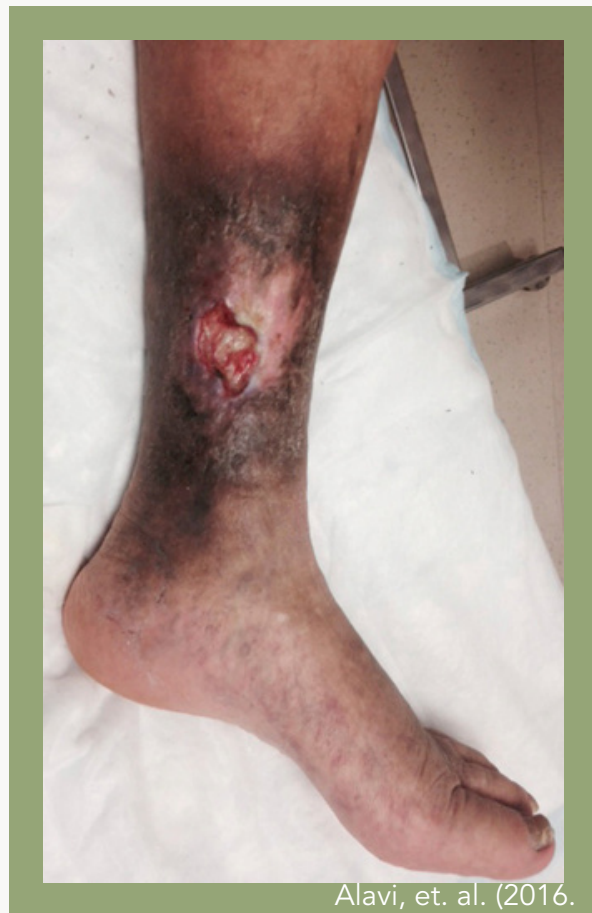Maroon or purple discoloration over intact skin or blood filled blister



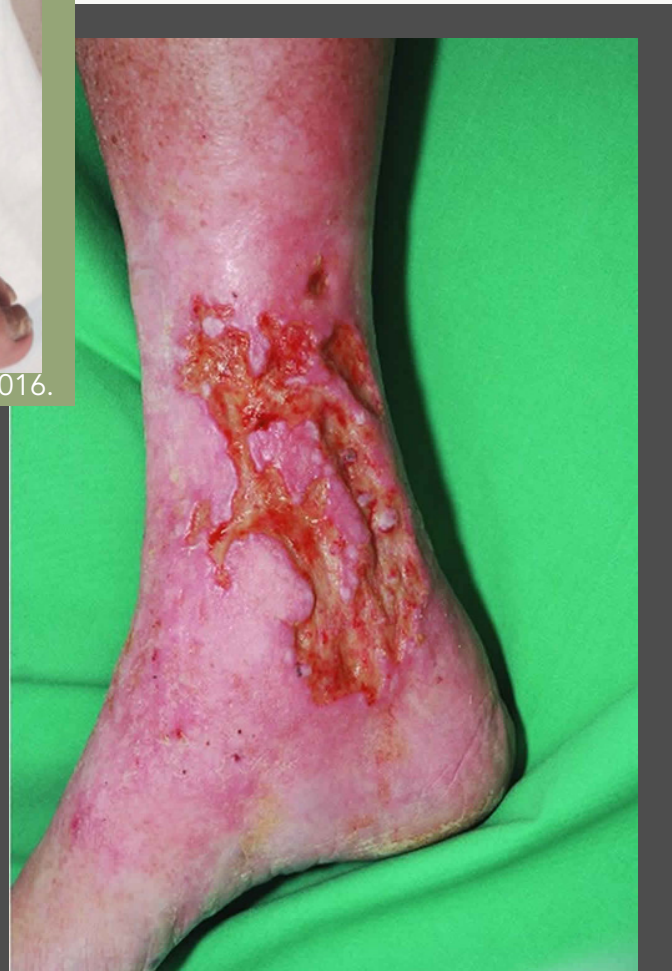Lineage, n.d.

VENOUS v. ARTERIAL v. DIABETIC

VENOUS

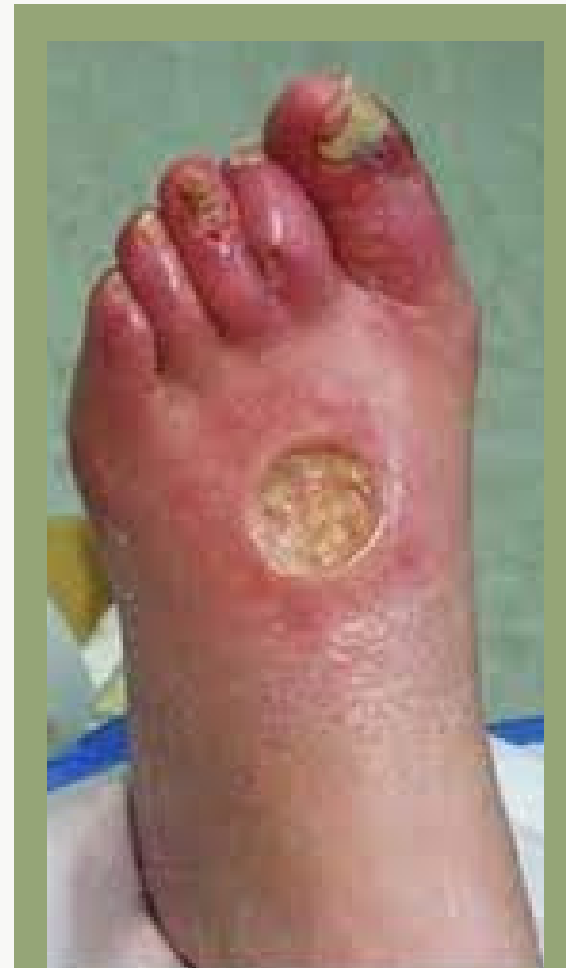

Alavi, et. al. (2016).

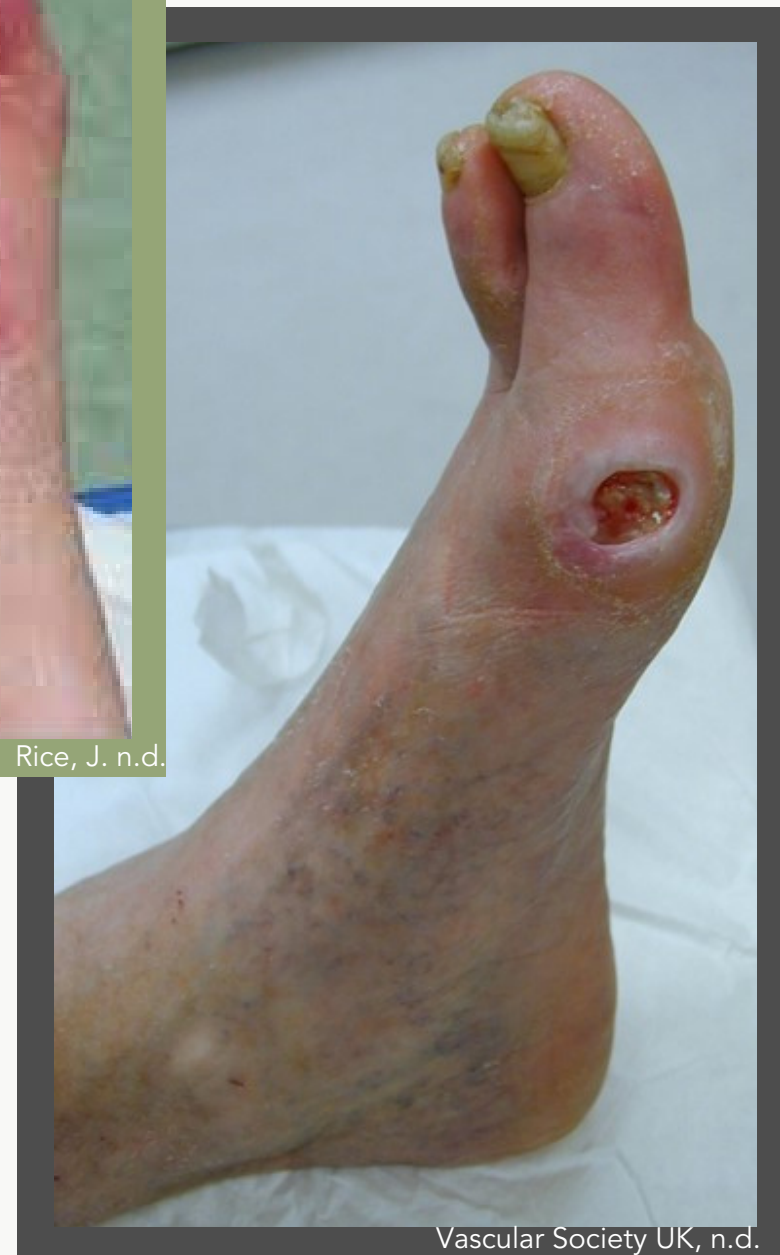

Health Jade, n.d.

ARTERIAL

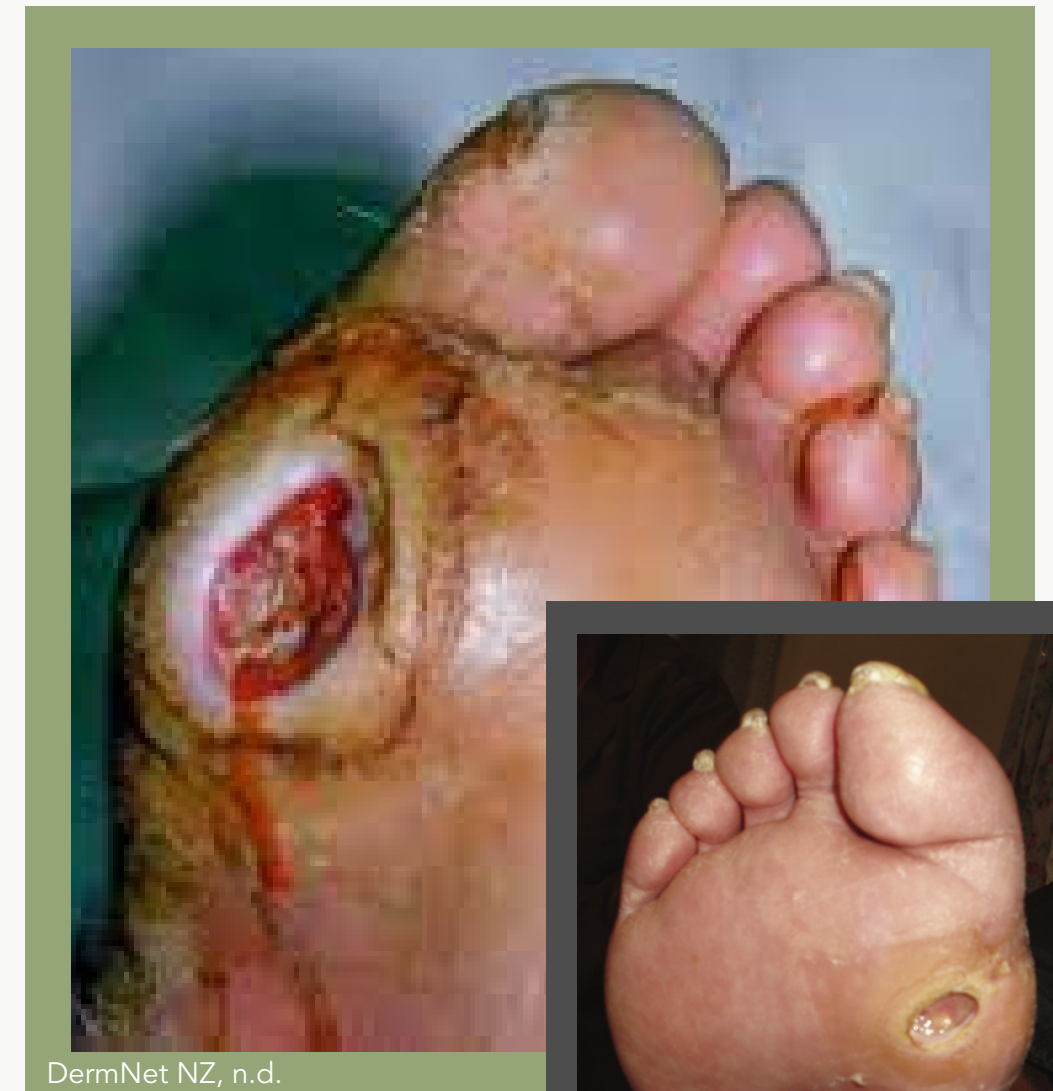

Rice, J. n.d.

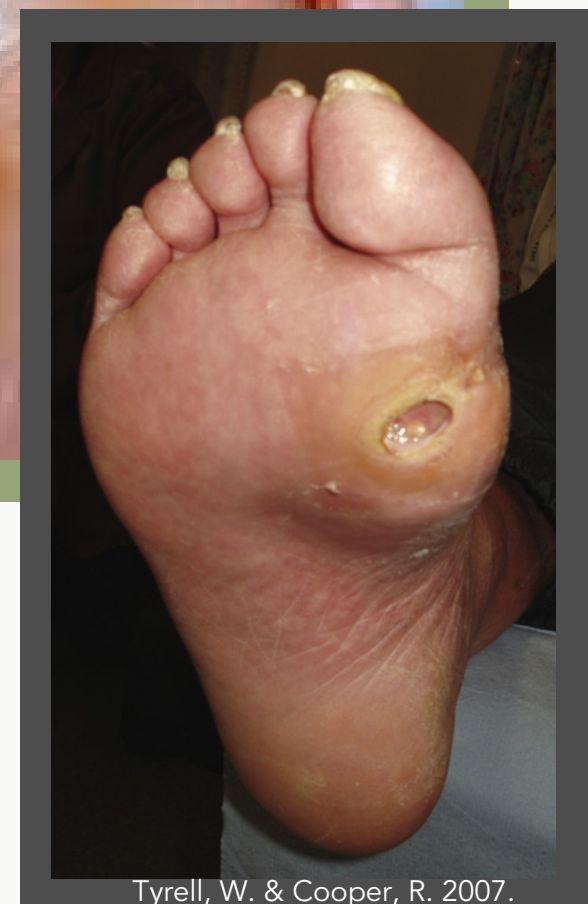

Vascular Society UK, n.d.

DIABETIC



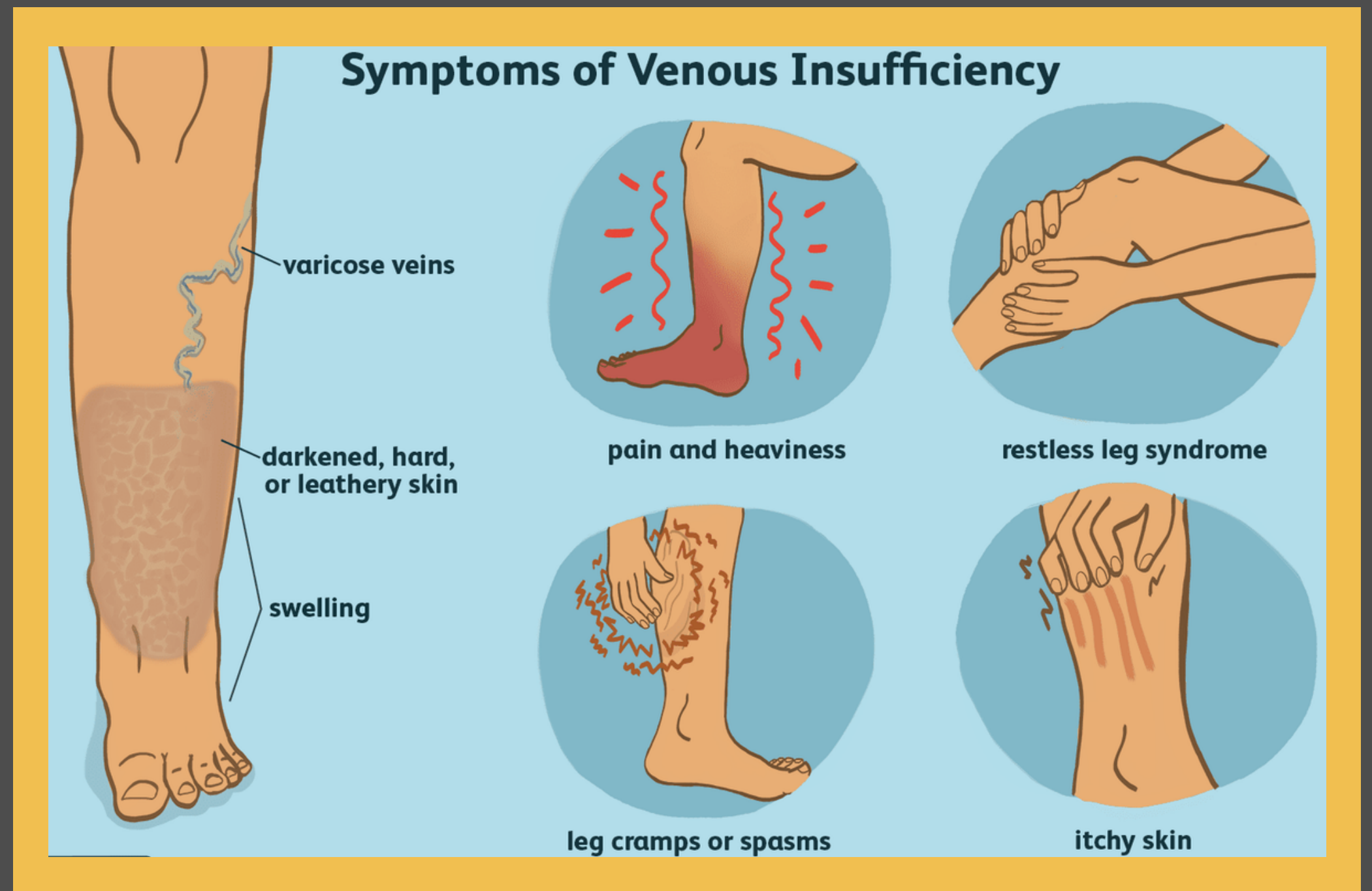
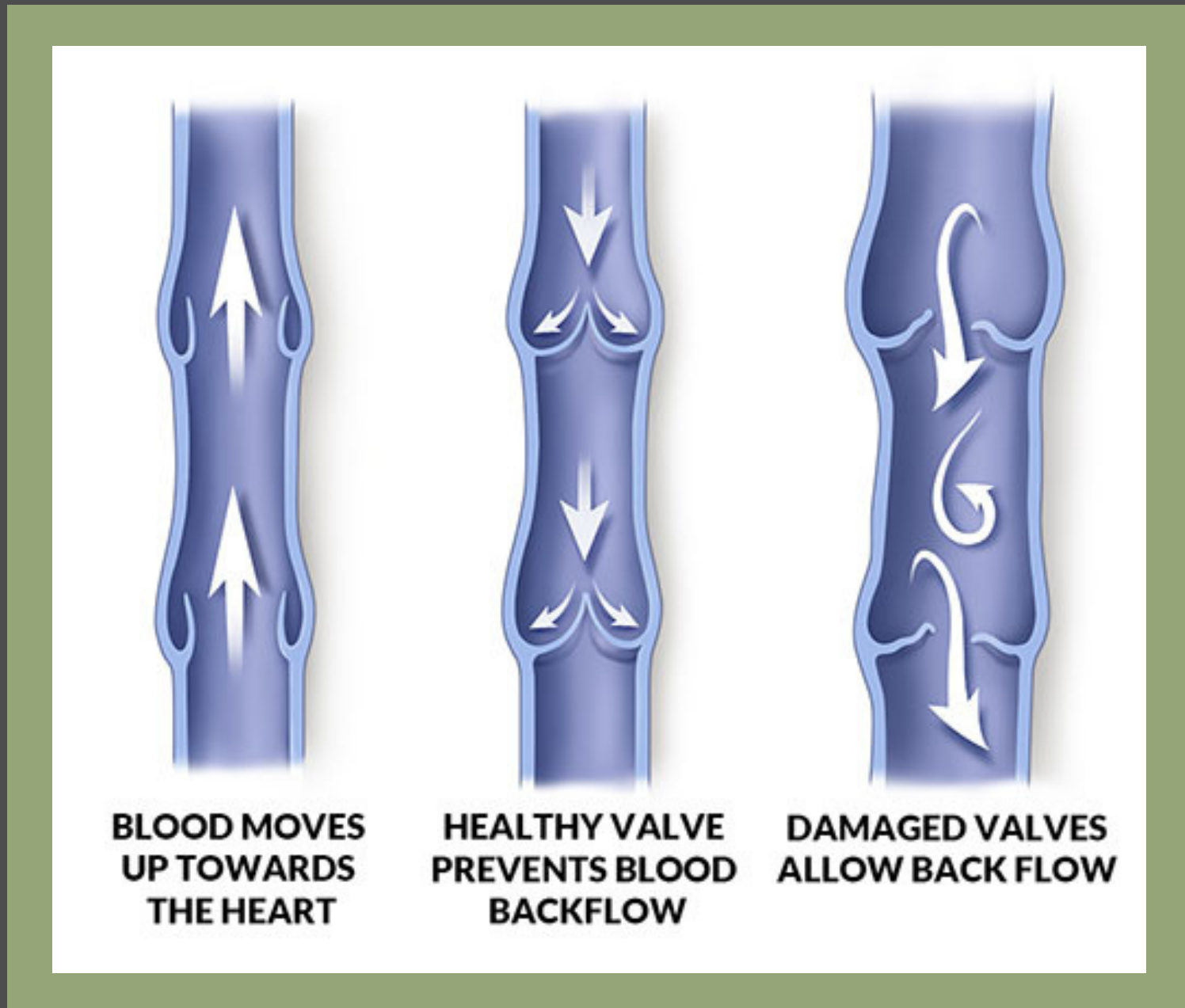
DermNet NZ, n.d.



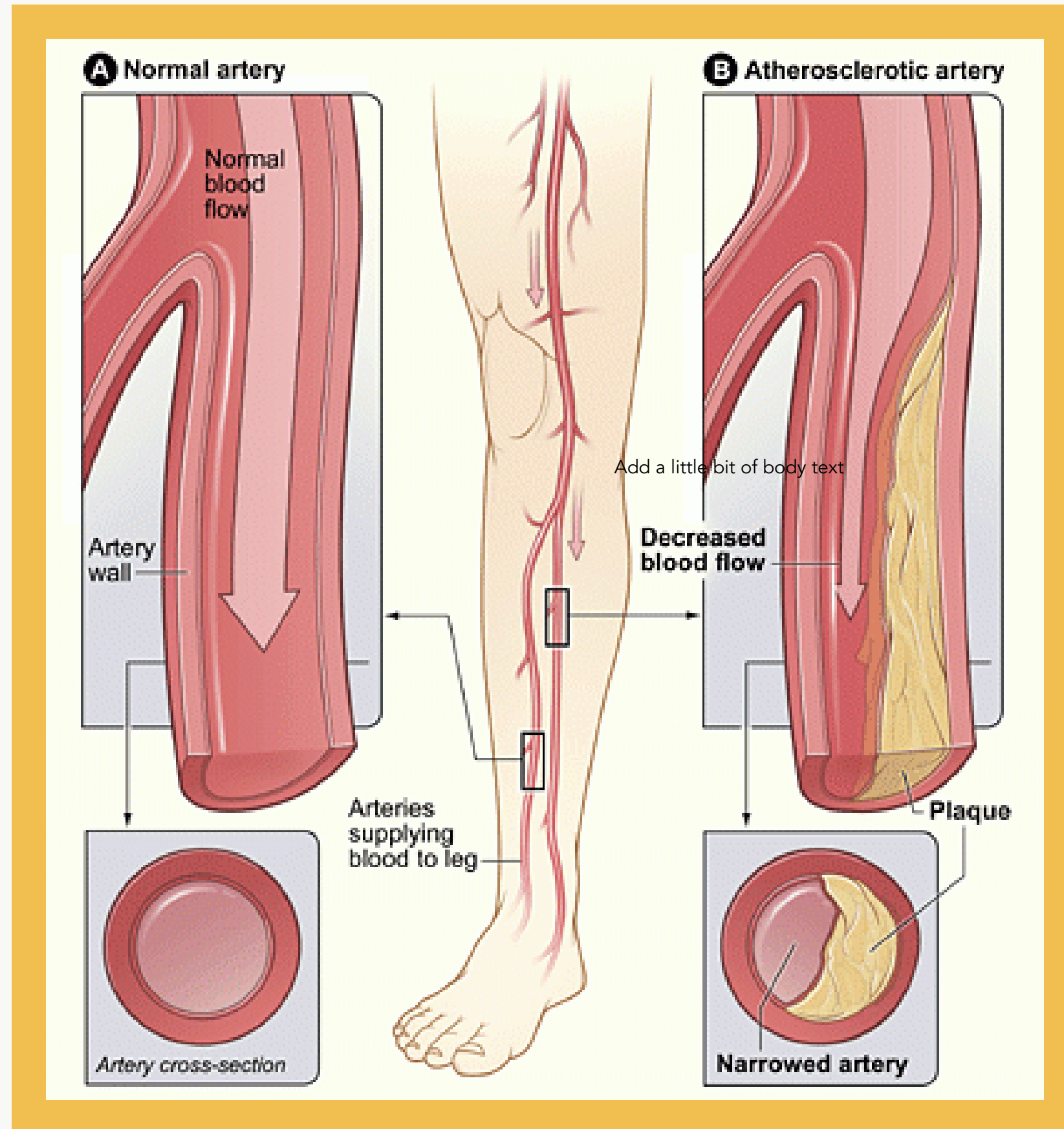
Tyrell, W. & Cooper, R. 2007.

VENOUS ULCER

Full-thickness defect of the skin, most frequently in the ankle region, that fails to heal spontaneously and is sustained by chronic venous disease.



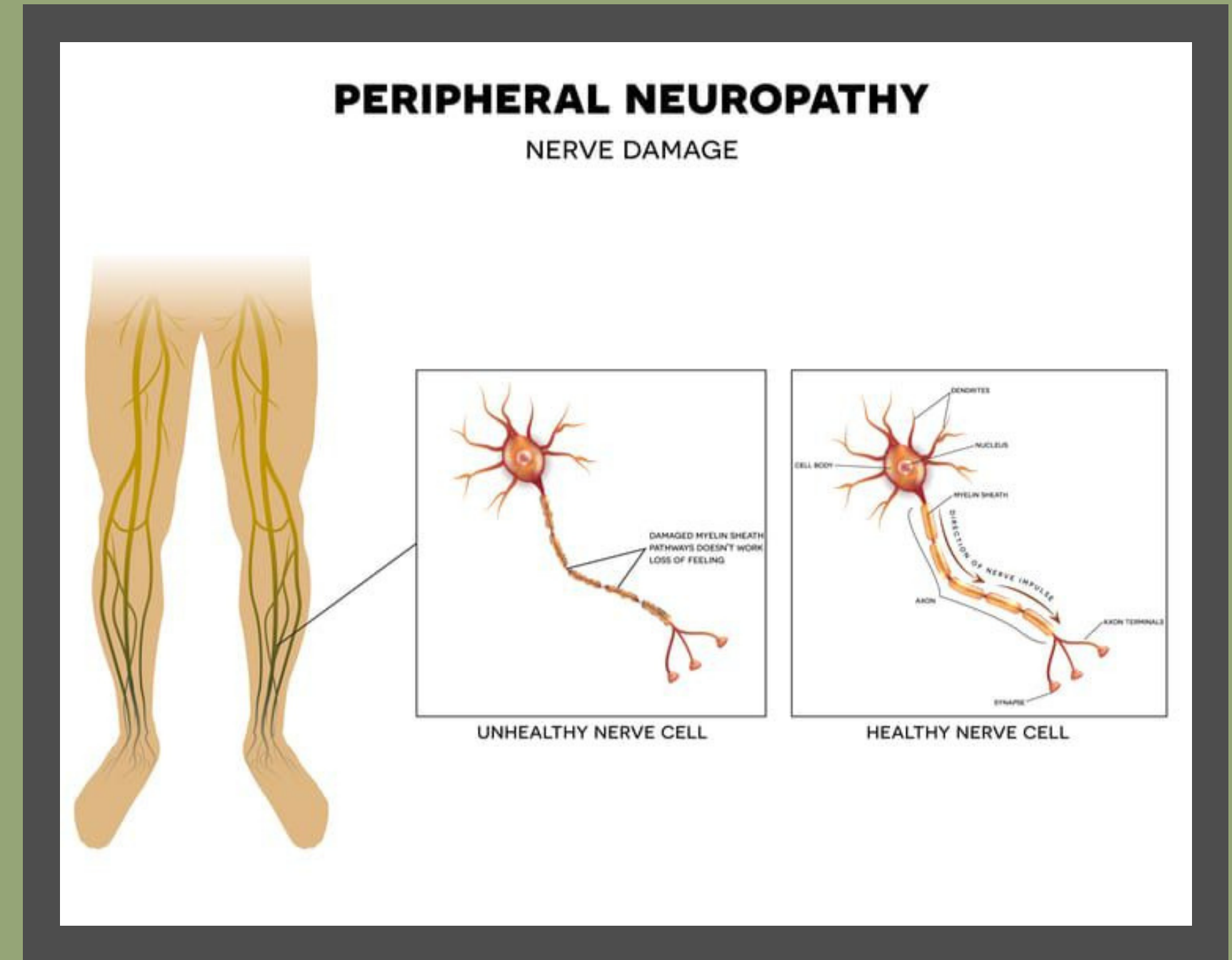
ARTERIAL ULCER



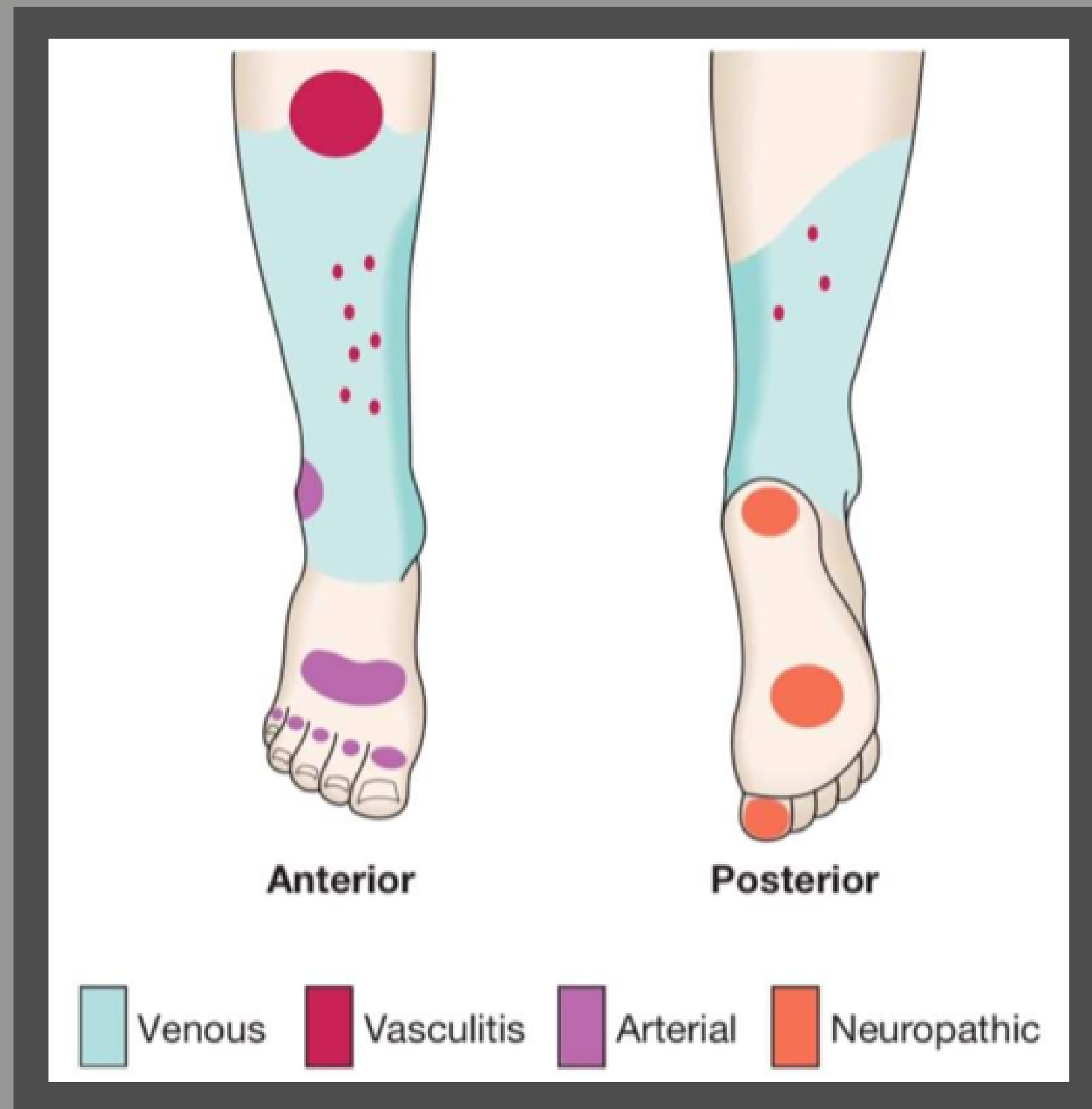
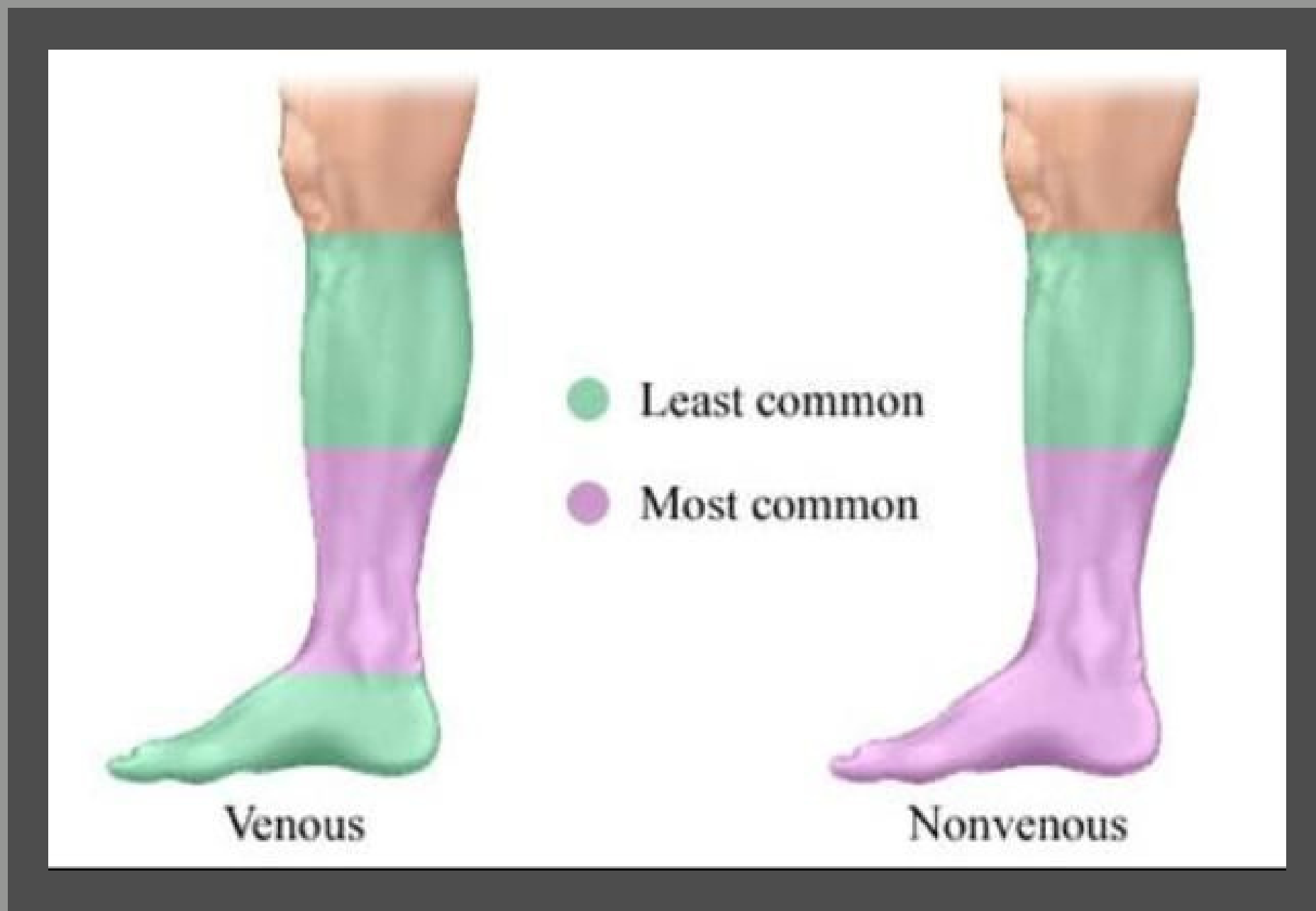
Full-thickness defect of the skin, caused by reduced arterial blood flow and subsequent tissue perfusion (ischemia). These are painful! Why do you think that is?

DIABETIC/NEUROPATHIC ULCER

Diabetic neuropathy is nerve damage caused by diabetes. Uncontrolled hyperglycemia damages nerves and impacts their ability to send signals. High blood sugar also weakens the walls of the capillaries that supply nerves with oxygenated blood.



GENERAL DIST.



ULCER CHARACTERISTICS

	Venous	Arterial	Diabetic
Location	<ul style="list-style-type: none"> • Medial malleolus (classic) • Anywhere between the ankle and knee (aka the "gaiter" region) 	<ul style="list-style-type: none"> • Tips of toes • Pressure points • Areas of trauma 	<ul style="list-style-type: none"> • Plantar surface over metatarsal heads • Areas of foot subject to repetitive trauma
Wound Base	<ul style="list-style-type: none"> • Usually shallow • Ruddy red • Yellowish, fibrinous slough 	<ul style="list-style-type: none"> • Shallow to deep • Pale or necrotic 	<ul style="list-style-type: none"> • Shallow to deep • Typically red if the wound isn't ischemic
Wound Edge	<ul style="list-style-type: none"> • Irregular • Poorly defined 	<ul style="list-style-type: none"> • Well defined • "Punched out" appearance 	<ul style="list-style-type: none"> • Well defined • "Punched out" appearance with a rim of callus
Periwound	<ul style="list-style-type: none"> • Macerated • Crust and/or scales • Edema • Hyperpigmentation 	<ul style="list-style-type: none"> • Faint halo of erythema • Slight induration 	<ul style="list-style-type: none"> • Callus
Exudate	<ul style="list-style-type: none"> • Moderate, high, copious 	<ul style="list-style-type: none"> • Minimal 	<ul style="list-style-type: none"> • Minimal to moderate
Additional Characteristics	<ul style="list-style-type: none"> • Systemic infections uncommon 	<ul style="list-style-type: none"> • Infections common • Symptoms often muted 	<ul style="list-style-type: none"> • Infections common • Symptoms can be vague • Suspect osteomyelitis if probes to bone

ASSESSMENT / FINDINGS

	Venous	Arterial	Diabetic
Skin Changes	<ul style="list-style-type: none"> • Hemosiderin staining • Atrophie Blanche • Lipodermatosclerosis • Dry, scaly skin • Normal hair pattern 	<ul style="list-style-type: none"> • Pale, shiny skin • Dependent rubor* • Elevation pallor* • Sparse to no hair 	<ul style="list-style-type: none"> • Cracking and fissures • Corns and calluses • Charcot foot
Nails	<ul style="list-style-type: none"> • Normal nails 	<ul style="list-style-type: none"> • Thick, cornified nails 	<ul style="list-style-type: none"> • Thickened nails • Fungal infections
Edema	<ul style="list-style-type: none"> • Pitting edema 	<ul style="list-style-type: none"> • None 	<ul style="list-style-type: none"> • None
Skin Temp	<ul style="list-style-type: none"> • Equal warmth bilaterally 	<ul style="list-style-type: none"> • Temperature difference 	<ul style="list-style-type: none"> • Equal warmth bilaterally • Increased temperature at impending ulcer site
Capillary Refill	<ul style="list-style-type: none"> • No delay 	<ul style="list-style-type: none"> • Delay (> 3 seconds) 	<ul style="list-style-type: none"> • No delay
Pain	<ul style="list-style-type: none"> • Throbbing • Burning • Aching • Improves with elevation and compression 	<ul style="list-style-type: none"> • Worsens with elevation • Improves with dependence • Rest pain • Nocturnal pain • Claudication pain 	<ul style="list-style-type: none"> • Hot poker • Pins and needles • Socking distribution • Progresses from decreased to no sensation • Nocturnal pain

2

ASSESS AND DOCUMENT



5 P'S

1

Prevention

2

Preference

3

Prescription

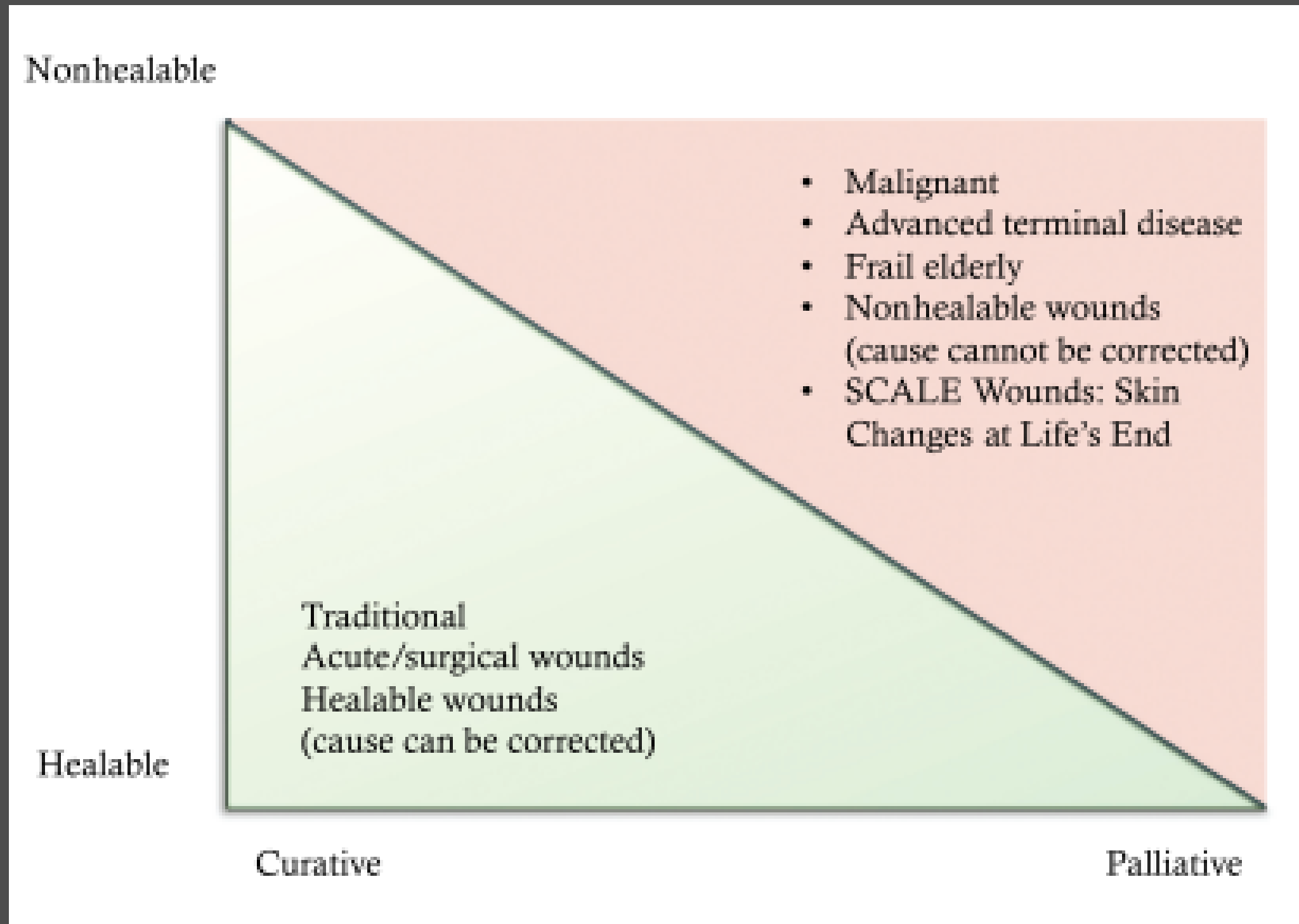
4

Preservation

5

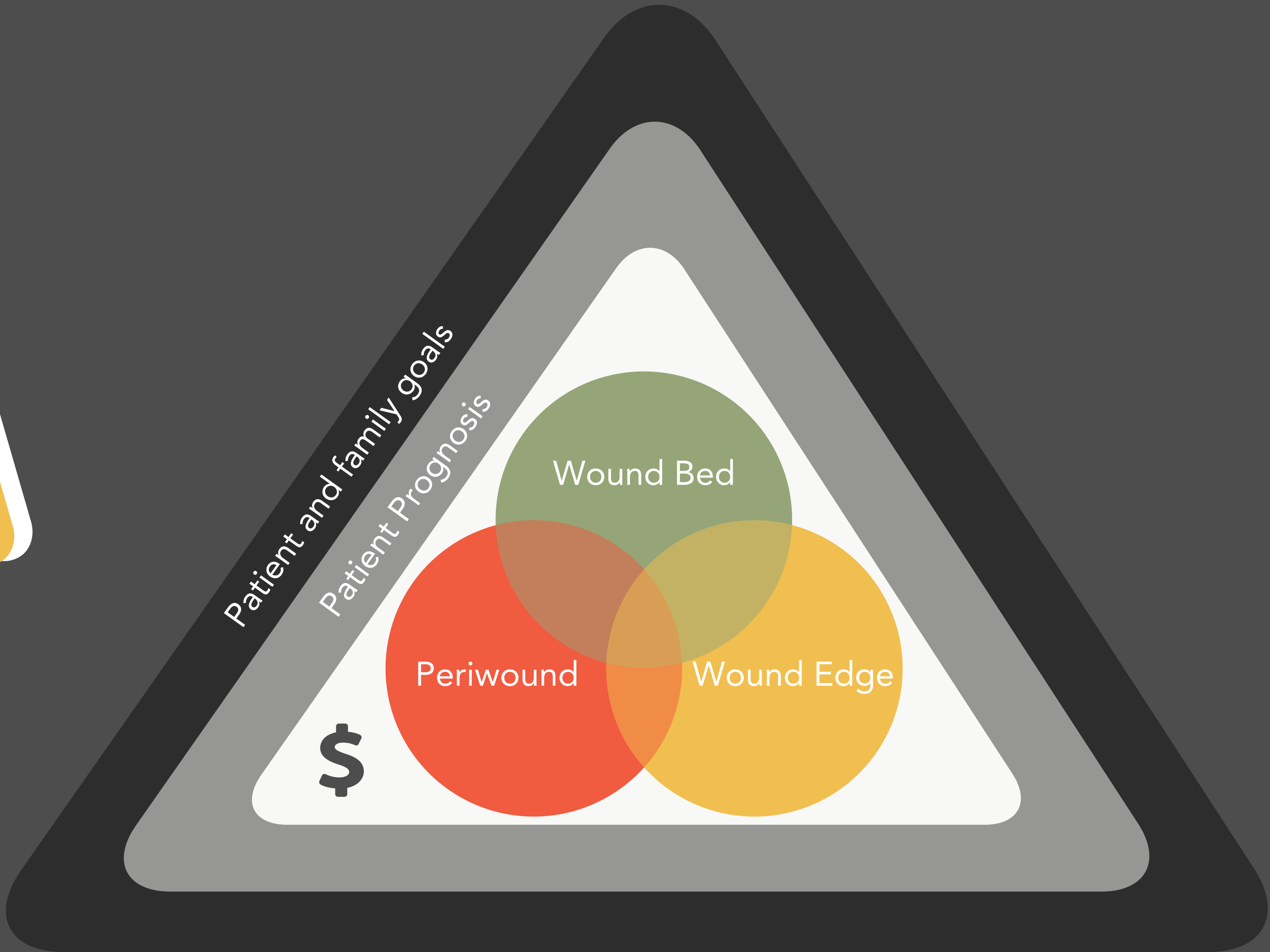

Palliation

WILL IT HEAL?



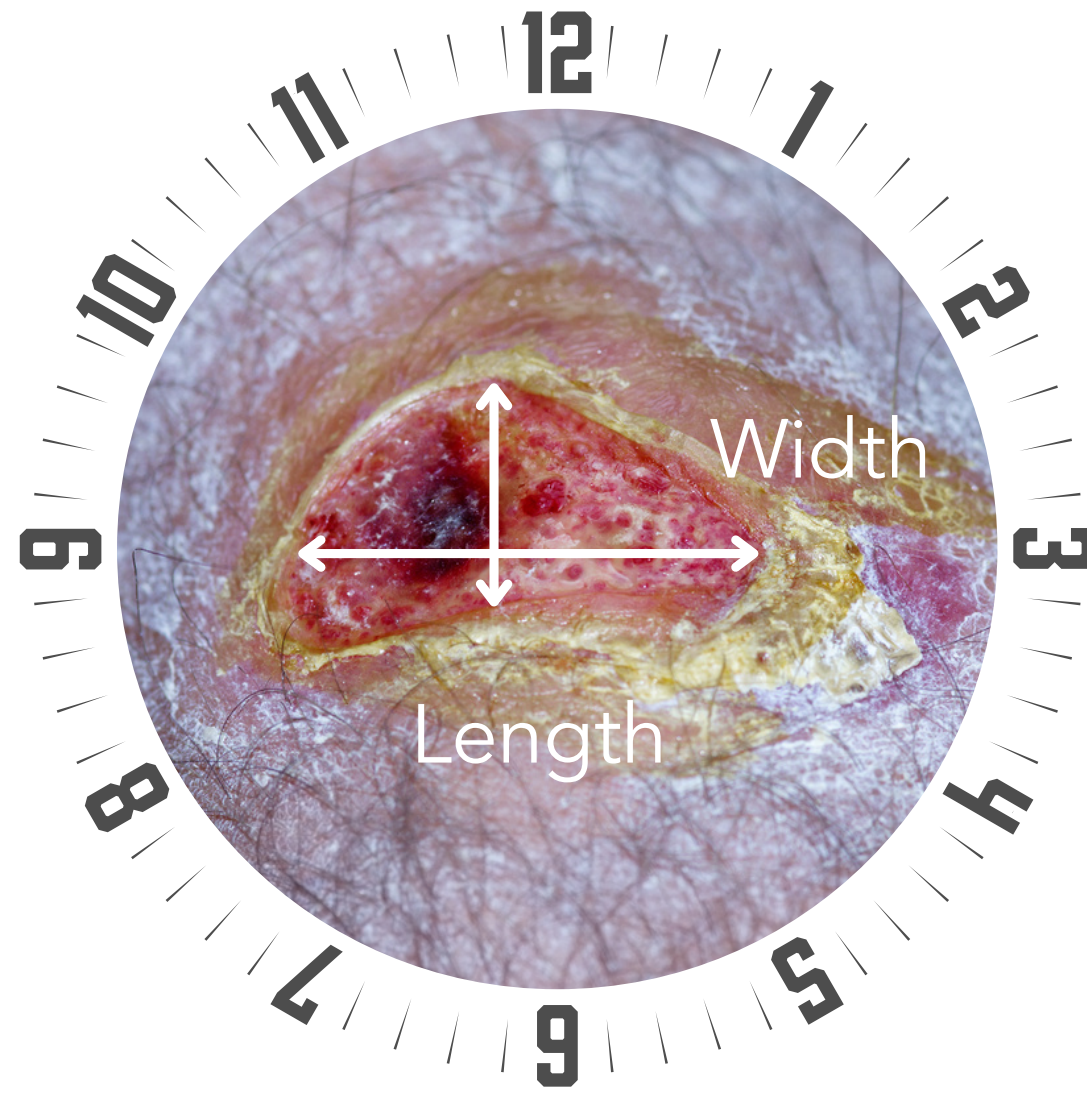
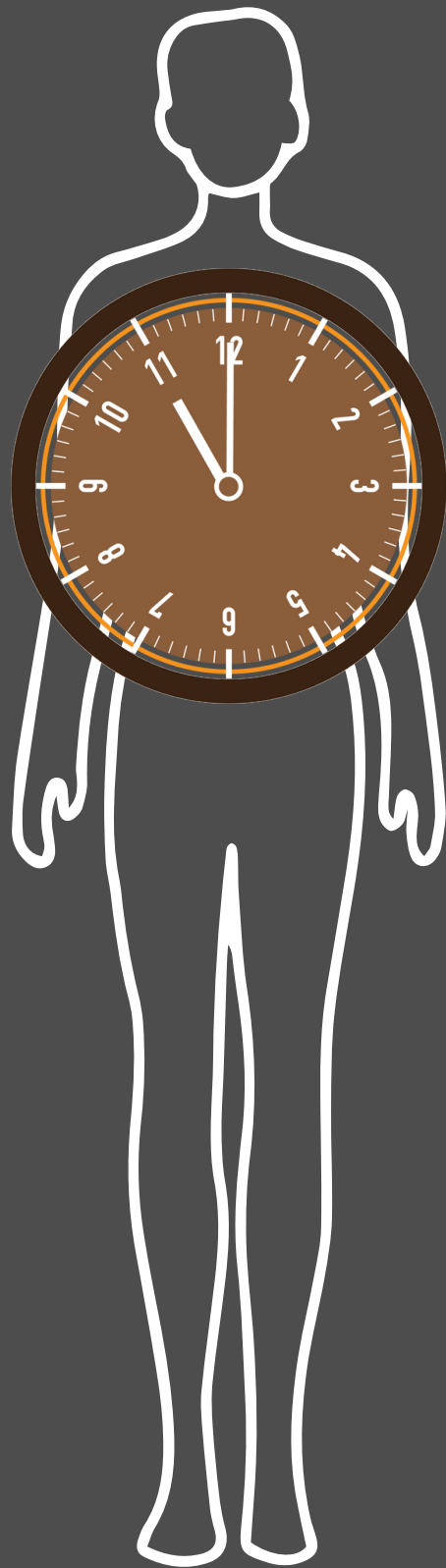
Conversation Starter:

F.R.A.I.L. Healing Probability
Assessment Tool




MEASURING

A

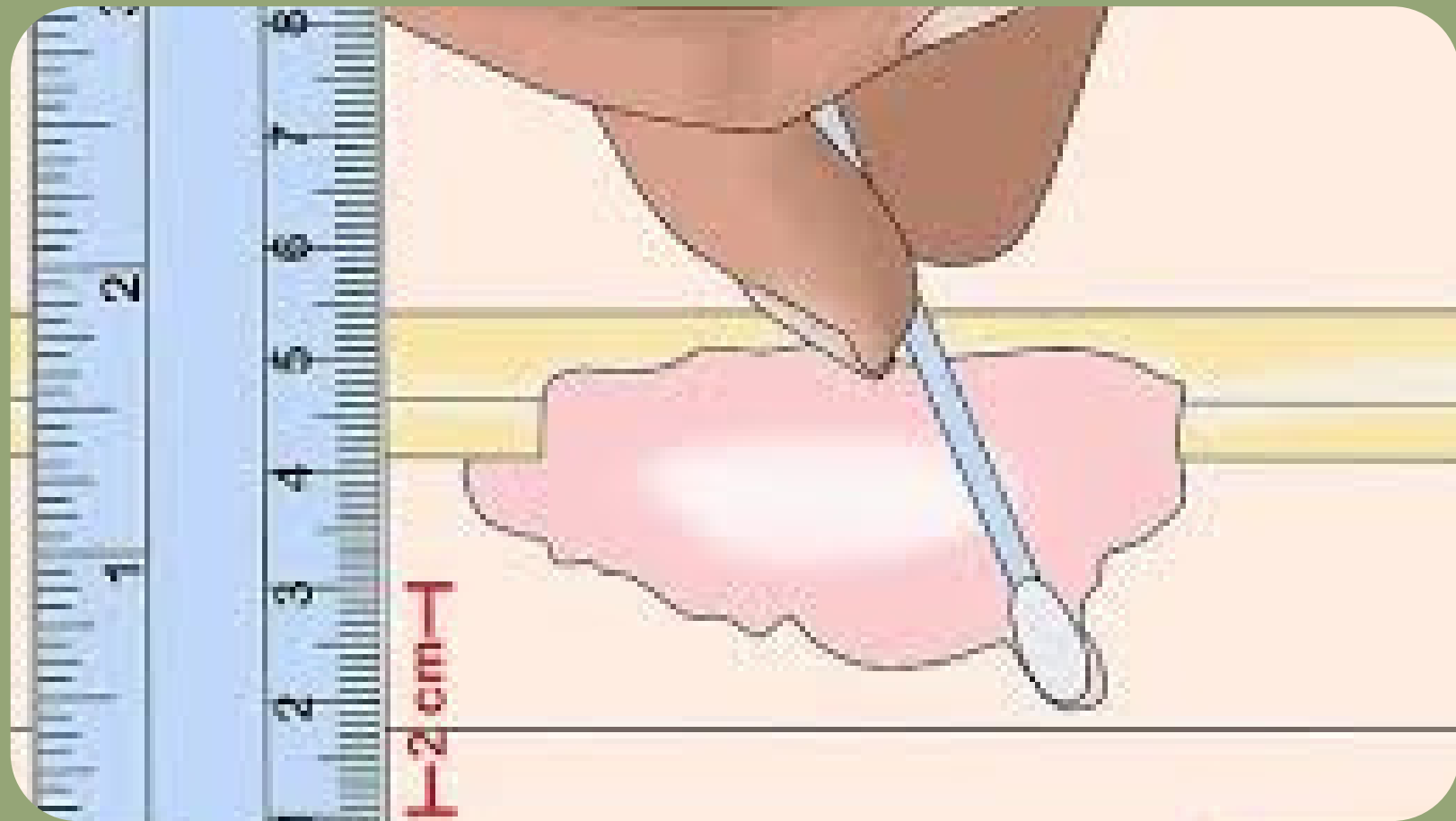

B

C

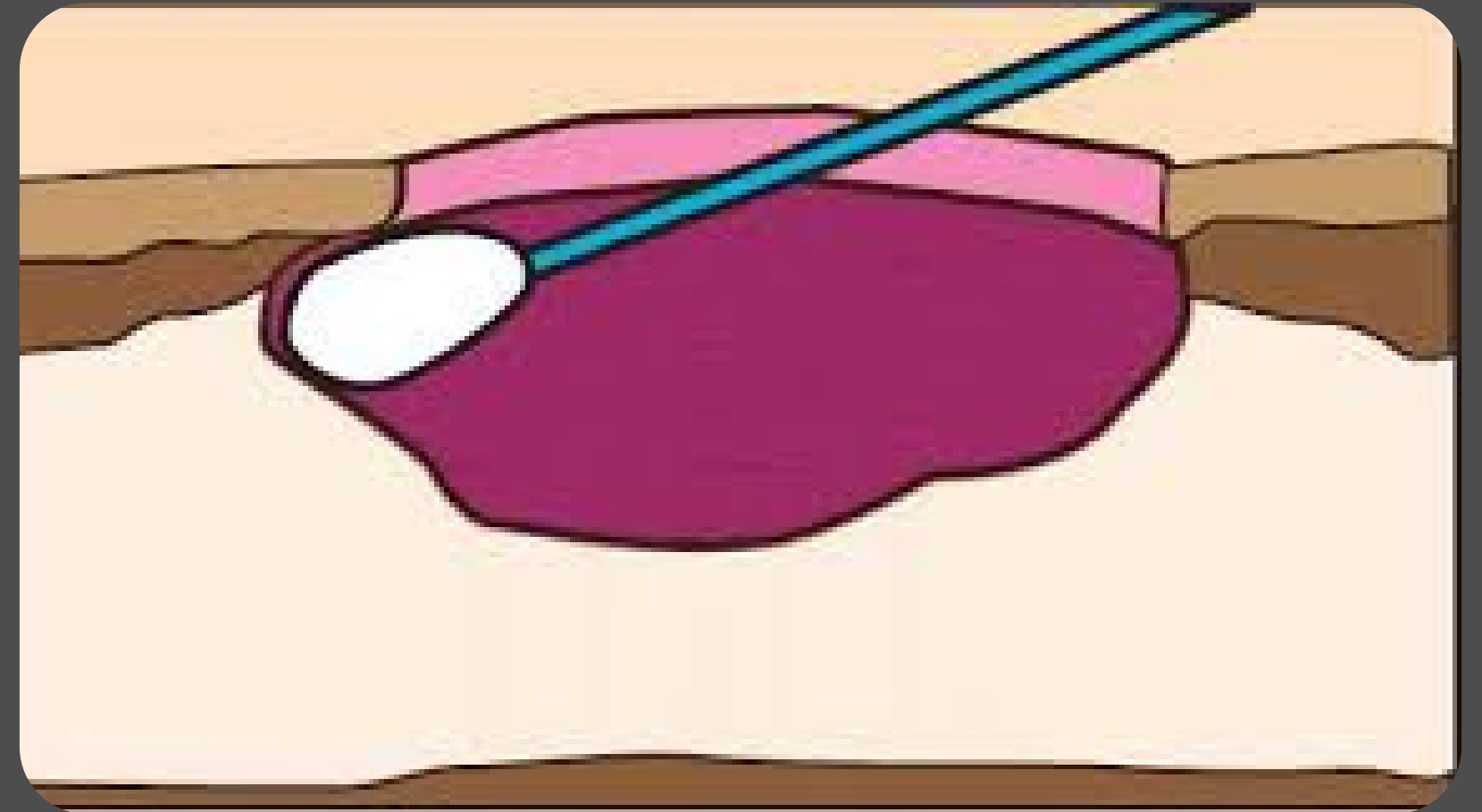


TUNNELING



Tunneling, aka Sinus Tract, tunneling is tissue loss that can occur in any direction from the surface of the wound or edge of the wound, Leaving a dead space that has the potential to develop an abscess.

Undermining is tissue loss that extends under the wound edge and intact skin on the periphery of the wound.



UNDERMINING

WOUND EXUDATE

Serous




Sanguineous



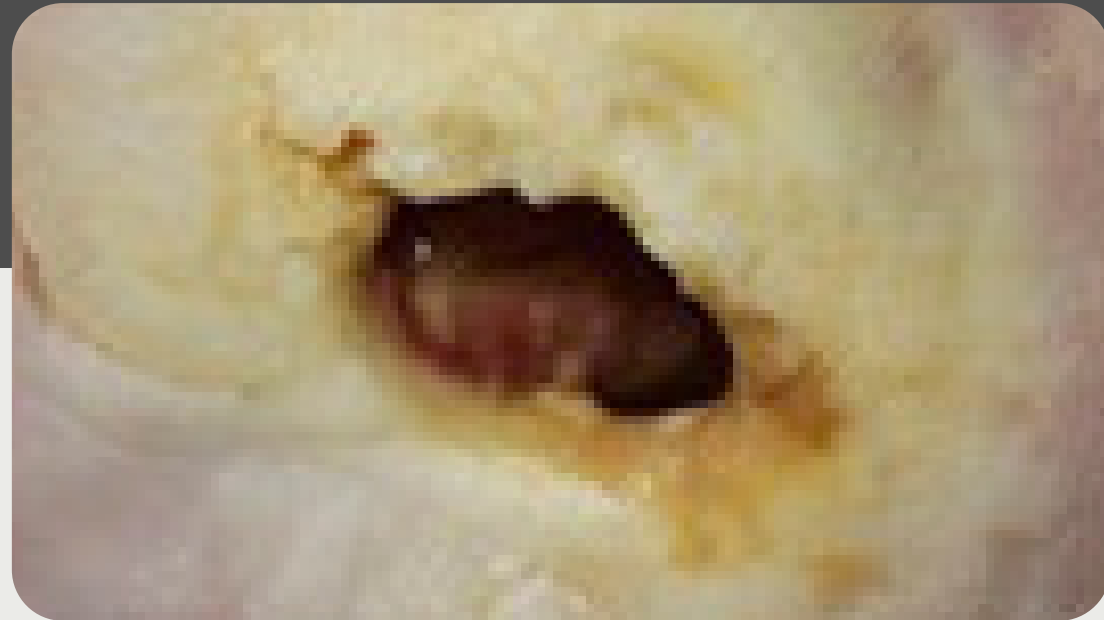Serosanguineous



Purulent

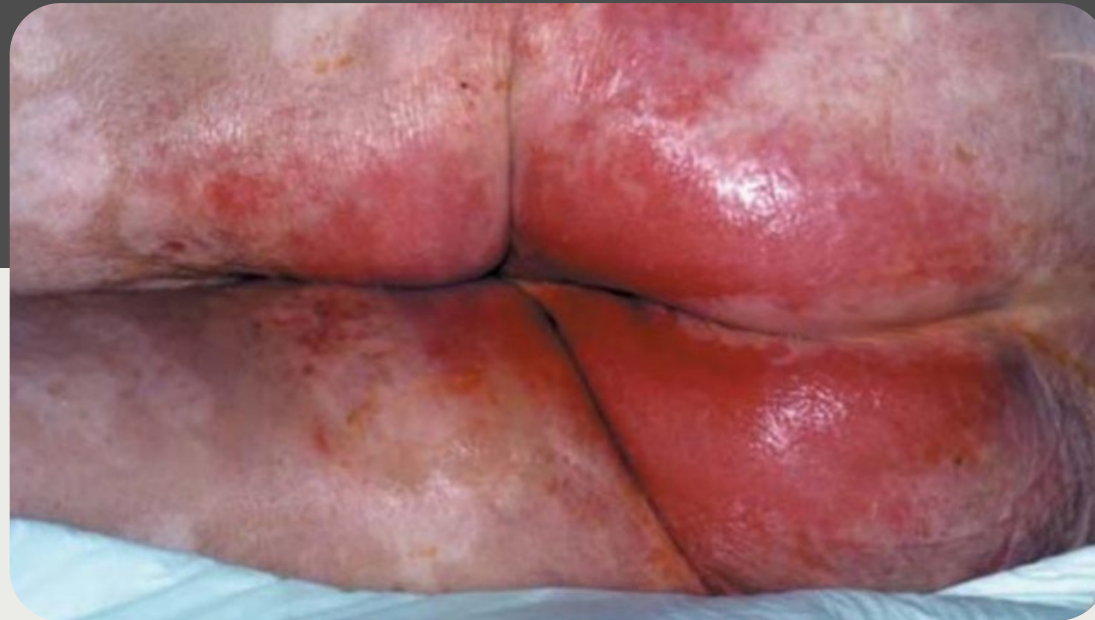

PERIWOUND CHARACTERISTICS



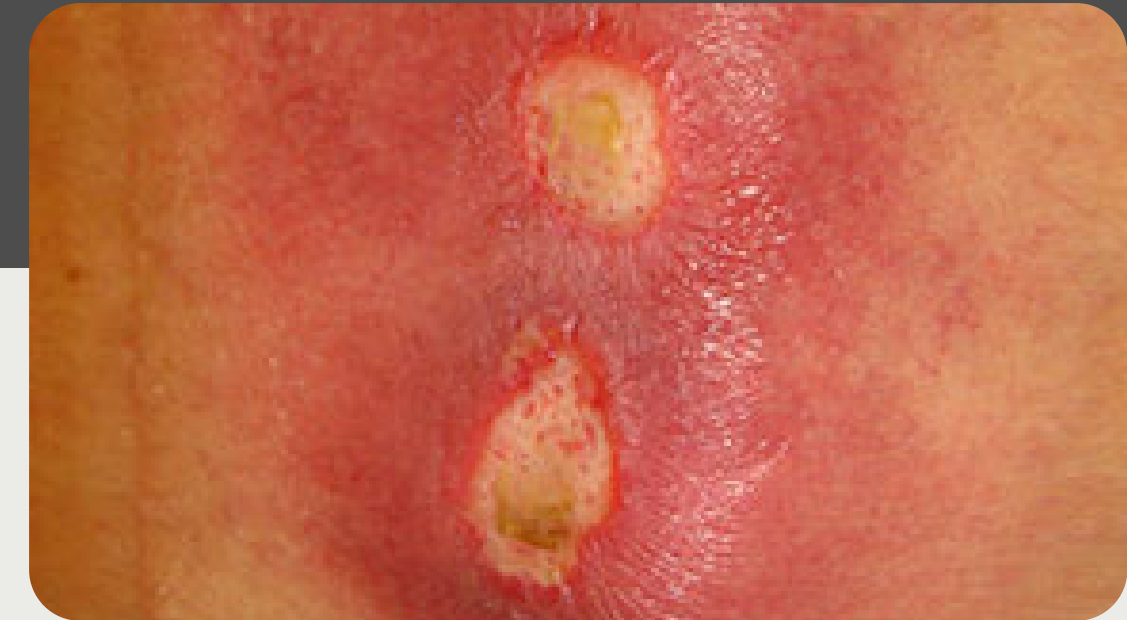MACERATION

Overhydration of the skin.



DENUDED SKIN

Erosion of the top layer of the skin.

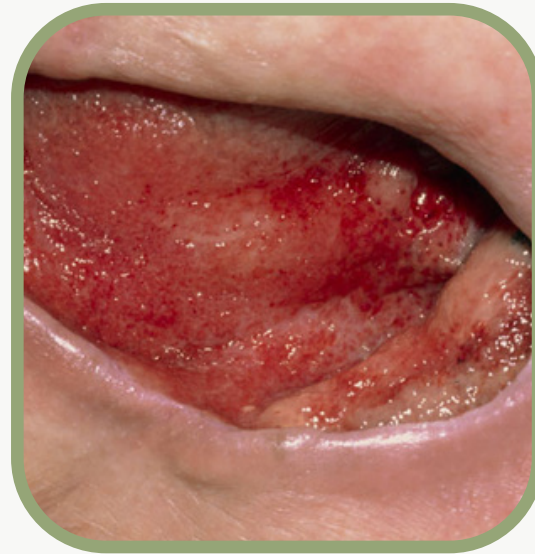

ERYTHEMA

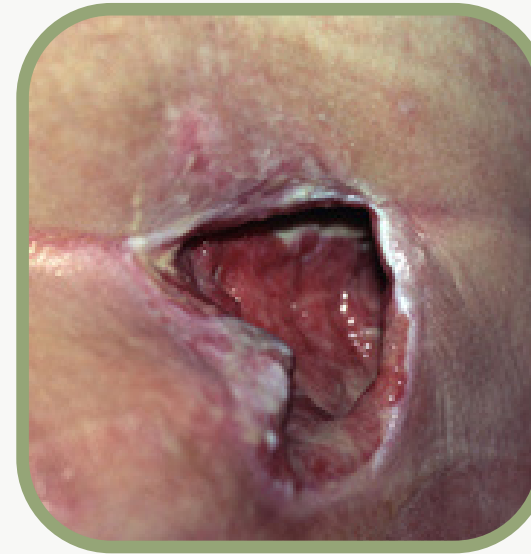Warm to touch, red appearing.



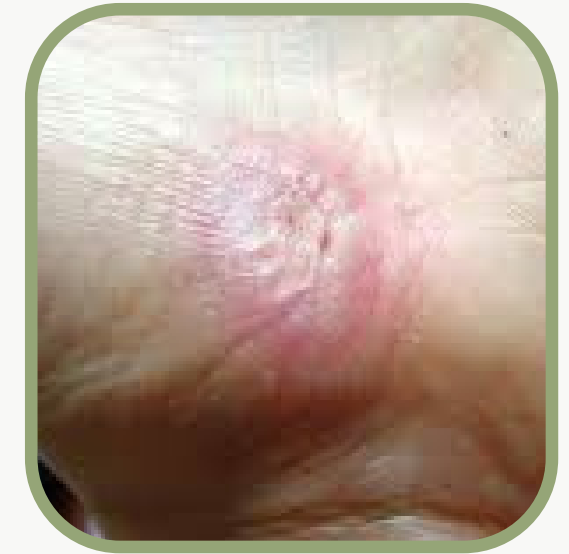ATTACHED



EPIBOLE



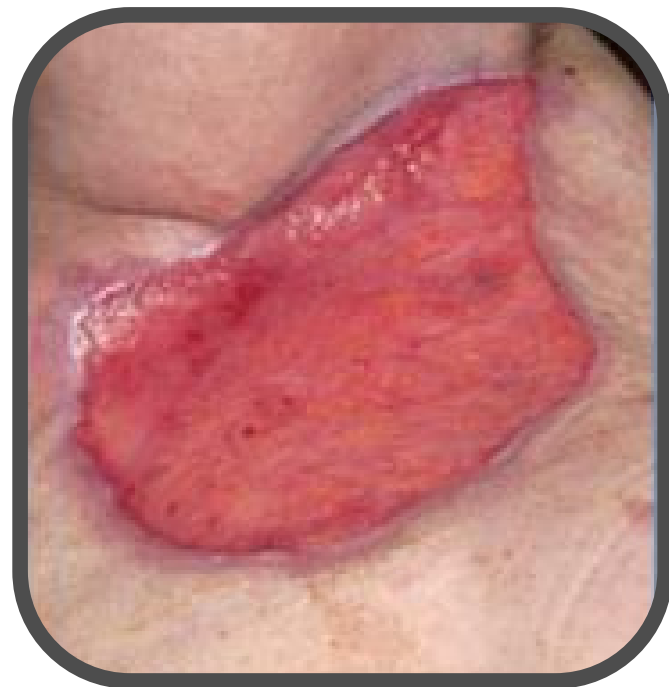NON-ATTACHED



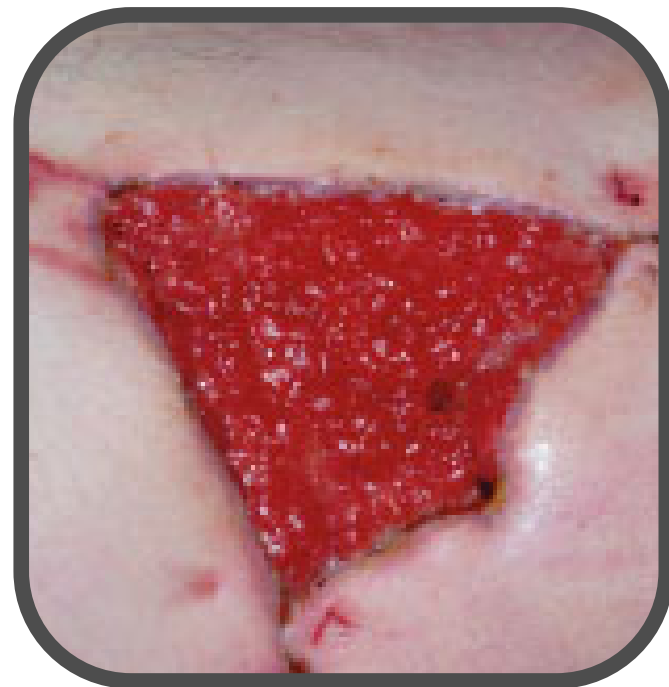EPITHELIALIZED

WOUND EDGES

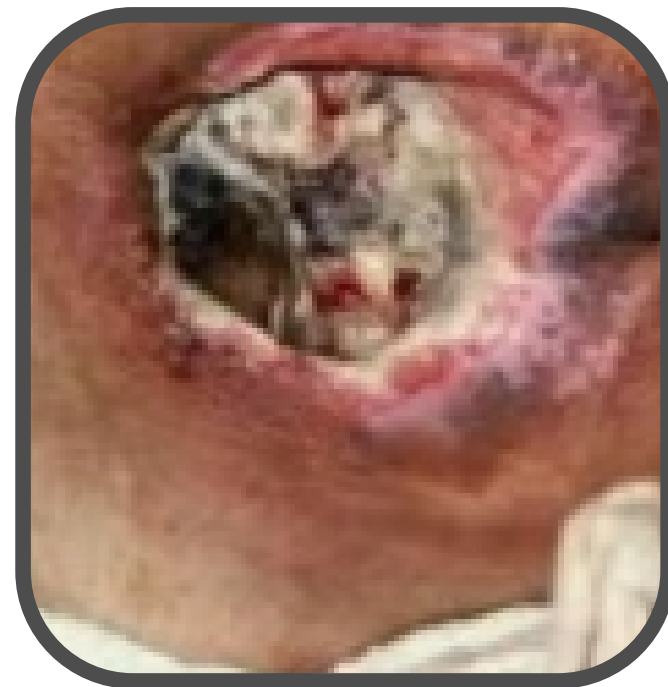WOUND BED TISSUES



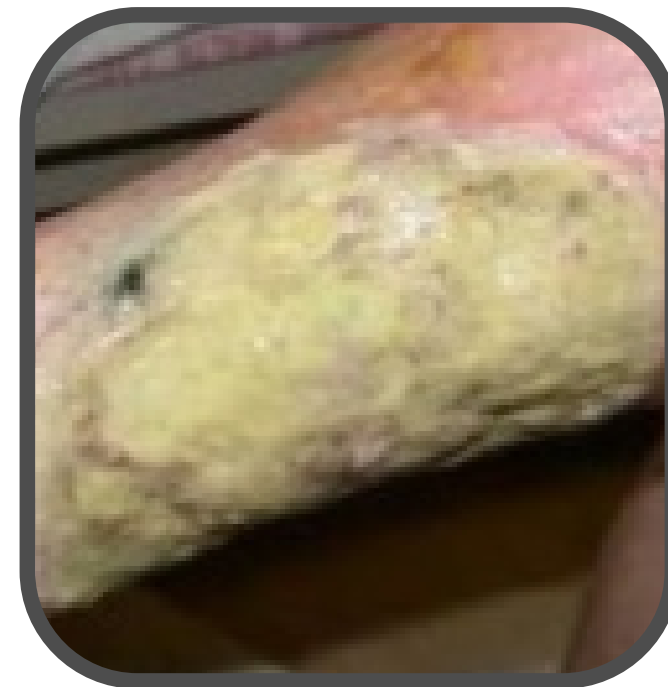Non-Granulating



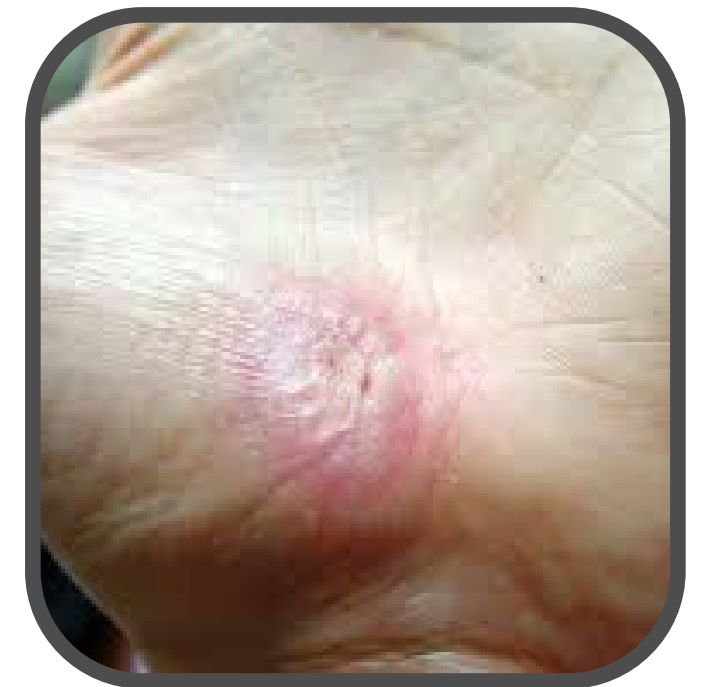Granulating



Eschar

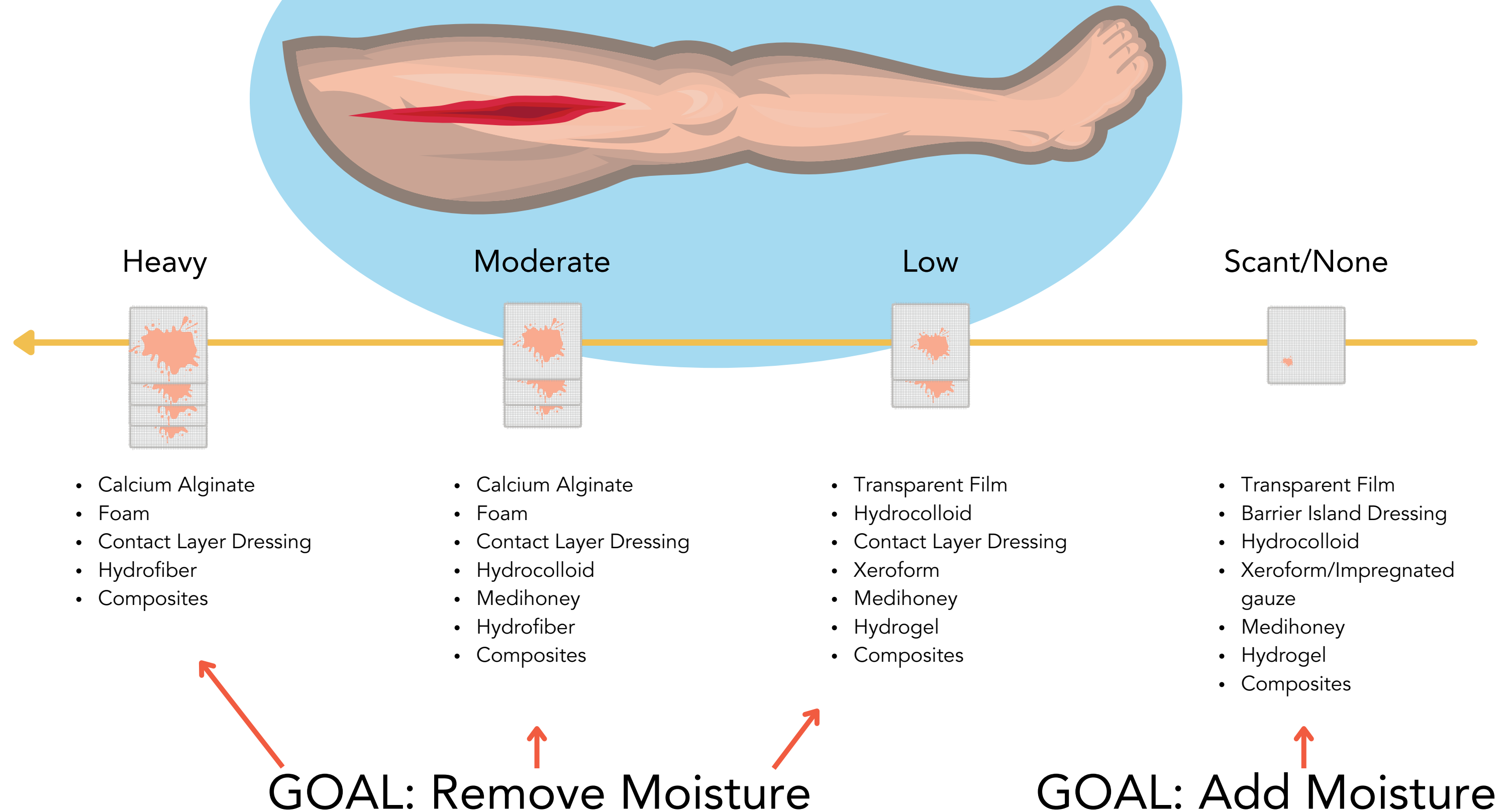


Slough



Epithelialization

DRESSINGS BY DRAINAGE



DOCUMENTATION GUIDE

1

Location

- Anterior, posterior, lateral, medial, mid, Ventral, dorsal, left, right, etc.
- Anatomical Location

2

Wound Stage

- PU and Skin Tears only

3

Wound Size

- length x width x depth in cm

4

Exudate/Drainage (use standardized measurements and descriptors)

- Amount
- Color
- Odor

5

Wound Edges

- Wound Shape
- Edges attached or not
- Callused
- Rolled Under (Epibole)

6

Periwound

- Color
- Edema (include whether pitting or not)
- Firmness/Induration
- Temperature
- Characteristics
 - Intact
 - Macerated
 - Rashy
 - Excoriated
 - Dry/Scaly

7

Wound Bed

- % Granulation Tissue (including absence of)
- % Epithelialization
- % Non-Granulation Tissue (if present)
- % Non-Viable Tissue
 - % Slough
 - % Eschar
- Tunneling
 - Use Clock Technique to Identify Location
 - Include Depth of Tunneling
- Undermining
 - Use Clock Technique to Identify Location
 - Include Depth of Undermining

8

Pain

- A&D on a standardized scale before, during and after care.
- Consider pre-medication PRN.

9

Overall Progress

- Improving/Stalled/Deteriorating/Unchanged
- S/Sx Infection

10

Wound Care Performed

- Dressing Change
- Whether MD contacted
- Hand Hygiene
- Supplies Provided
- Family Updated
- Protocol Followed/Changed
- Care Plan Changes
- Patient Tolerance



Photo

- Per Agency Policy
- Obtain Patient/Decision Maker Consent
- Avoid Identifying Features
- Include Measurement Device
- Use Consistent Patient Positioning

WOUND DOCUMENTATION TIPS

1

If you didn't document it, it wasn't done!

2

Wound care should always be on the care plan.

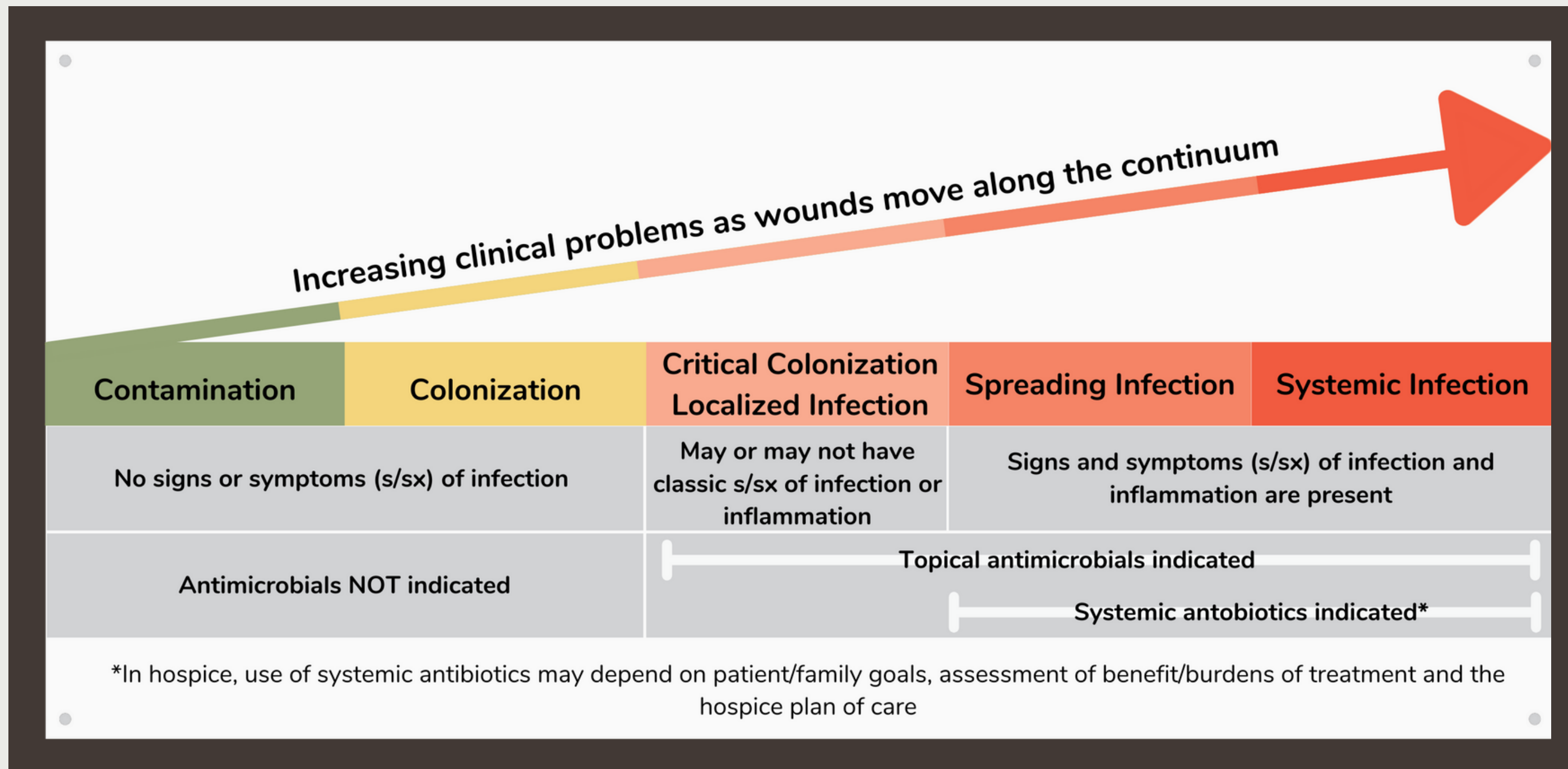
3

Standardize and be consistent.

WOUND INFECTIONS



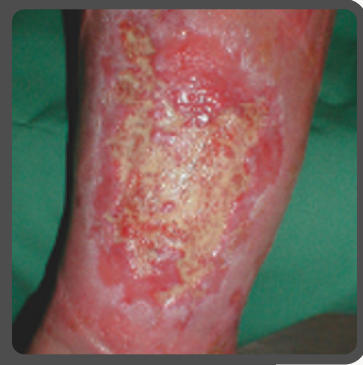BACTERIAL BURDEN CONTINUUM



Zone	What You See	What To Do
Green Zone: Contamination	<ul style="list-style-type: none"> • No signs or symptoms of infection • This is a normal state and the wound will progress toward healing 	<ul style="list-style-type: none"> • Hand washing prior to wound care • Aseptic technique for wound care • Provide routine wound assessments, including measurements • Assess for wound pain • Remain observant for wound changes • Educate the patient/family on infection prevention and when to call hospice
Yellow Zone: Colonization	<ul style="list-style-type: none"> • No signs or symptoms of infection • This is a normal state and the wound will progress toward healing 	<p>All of the Green Zone interventions</p>
Light Red Zone: Critical Colonization- Localized Infection	<p>Increased and/or new development of:</p> <ul style="list-style-type: none"> • Wound pain • Localized erythema (<2cm) • Friable granulation tissue • Exudate (may see amount and/or characteristics change) • Odor <p>Lack of progression toward healing</p>	<p>All of the green and yellow zone interventions, PLUS:</p> <ul style="list-style-type: none"> • Topical antimicrobial dressing • Increase wound assessment frequency • Manage wound pain, odor and drainage <p>Assessment Tool: N.E.R.D.S.</p> <ul style="list-style-type: none"> ○ Non-Healing Wound - Does wound healing seem stalled or is the wound getting worse? ○ Exudative Wounds - Is the drainage increasing in volume? Is it changing color or purulent? Is there any odor associated with the exudate? ○ Red and Bleeding - Is the wound redder than normal? Does it bleed easily (or increasingly easy)? ○ Debris - Is there debris (like yellow slough or black necrotic tissue in the wound)? Is it worsening? ○ Smell - Is there a new or worsening odor from the wound? <p>If the patient has 2-3 or more of these, talk to the provider. Topical intervention is recommended.</p>

Zone	What You See	What To Do
<p>Red Zone: Spreading Infection</p>	<ul style="list-style-type: none"> • Any of the light red zone signs/symptoms, plus increased: • Wound size (may include satellite or new satellite wounds) • Periwound erythema (>2cm) • Periwound temperature • Periwound edema • Blood sugar for those with diabetes • Malaise 	<p>Assessment Tool: S.T.O.N.E.S.</p> <ul style="list-style-type: none"> • Size is Bigger - Is the wound increasing in size? • Temperature is Increasing - Is the wound temperature increasing? Use a non-affected area for comparison (if on a limb, use the opposite limb for comparison). >3 degree difference using infrared thermometer and mirror image comparison sites is highly suggestive of infection • Osteo (Probes to Bone) - If you can probe to bone, the patient is at risk for osteomyelitis. • New Areas of Breakdown - Are there new areas of breakdown (satellite wounds)? • Exudate/Erythema - Is the exudate changing (i.e. increased volume, color or consistency)? Is there new or increasing erythema in or around the wound bed? • Smell - Is there a new or worsening odor from the wound? <p>If the patient has 3 or more of these, talk to the provider. Wound culture and systemic treatment may be indicated if it is in line with the patient's goals and the hospice plan of care. Note that in hospice, infections are often treated empirically, as cultures provide limited benefit at end of life.</p>
<p>Dark Red Zone:</p>	<ul style="list-style-type: none"> • Any of the light red and red zone signs/symptoms, plus increased: • Fever and/or chills • Cognition changes • Elevated heart rate and respirations • Elevated WBC's • Development of sepsis 	<p>All of the above green, yellow, light red and red zone interventions, PLUS:</p> <ul style="list-style-type: none"> • If treatments are ineffective and/or the patient/family decides to forgo treatments: educate on what to expect as the infection worsens and the patient progresses toward death. • Provide aggressive symptom management.

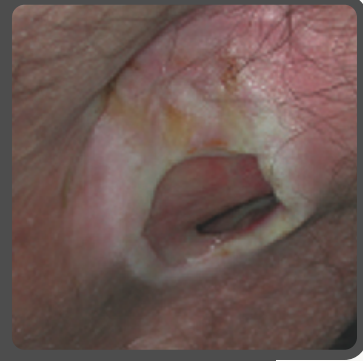N



NON-HEALING

Does wound healing seem stalled or is it getting worse?

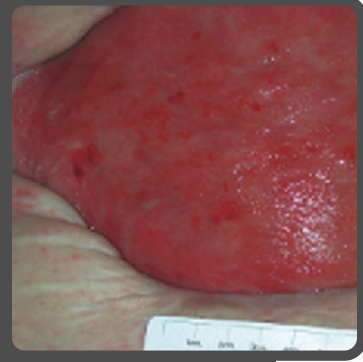
E



EXUDATE

Is the drainage increasing in volume or changing color? Is it purulent?

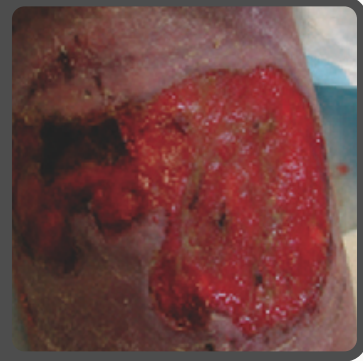
R



RED AND BLEEDING

Is the wound redder than normal, or more friable?

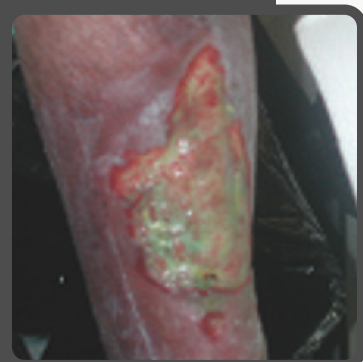D



DEBRIS

Is there debris in the wound bed (slough, eschar)? Is it worsening?

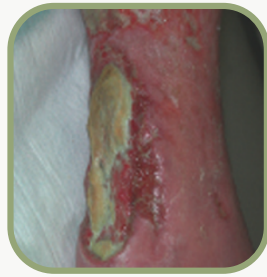S



SMELL

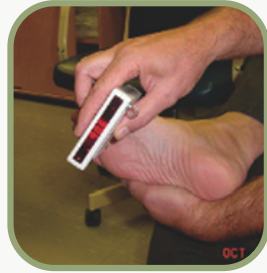Is there new or worsening odor?

S T O N E S



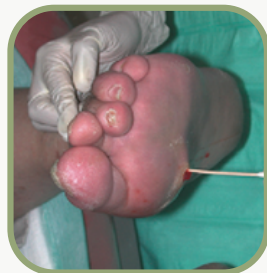SIZE IS BIGGER

Is the wound increasing in size?



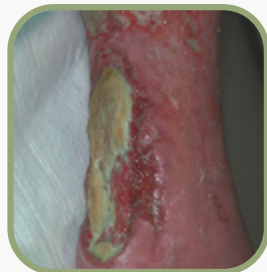TEMPERATURE INCREASING

Is the wound temperature increasing?



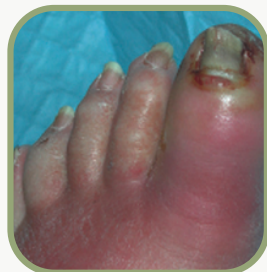OSTEO (PROBE TO BONE)

If you can probe to bone, the patient is at risk of osteomyelitis.



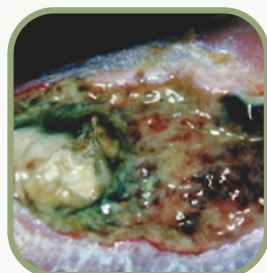
NEW AREA OF BREAKDOWN

Are there new areas of breakdown (satellite wounds)?



EXUDATE/ERYTHEMA

Exudate changing? New or increasing erythema?



SMELL


Is there new or worsening odor?

COMMONLY USED ANTIMICROBIALS IN HOSPICE

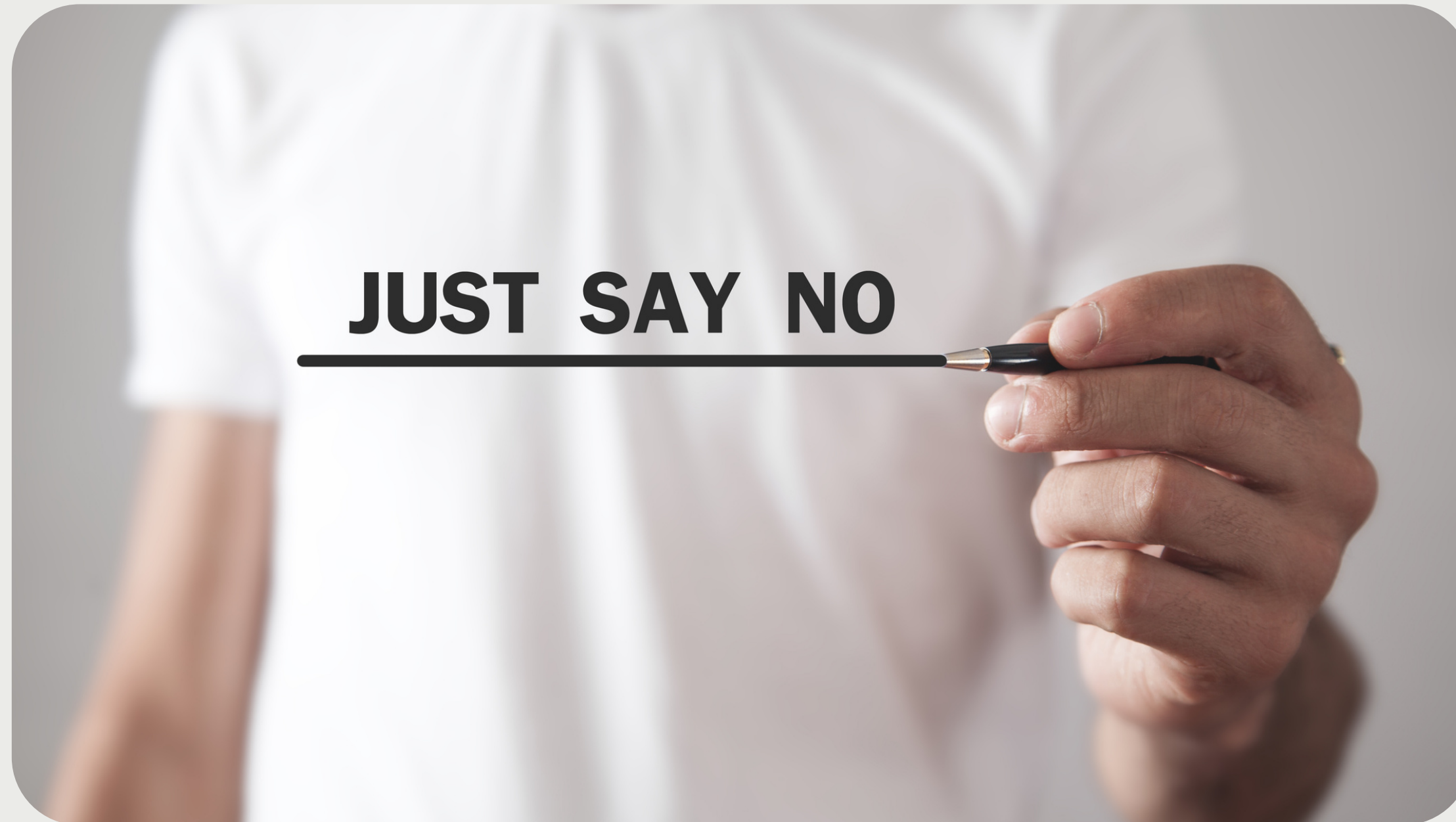Name	What it Does	Notes
Silters	<ul style="list-style-type: none"> • Antimicrobial effect on bacteria, fungi, yeasts and viruses 	<ul style="list-style-type: none"> • Avoid in those with silver sensitivities
Cadexomer Iodine	<ul style="list-style-type: none"> • Antimicrobial effect on bacteria, fungi, yeasts, protozoa and viruses 	<ul style="list-style-type: none"> • No known bacterial resistance • Avoid in patients with allergies to iodine, shellfish • Change when product turns white
Medical Honey	<ul style="list-style-type: none"> • Antimicrobial effect on over 50 strains of bacteria, plus protozoa, fungi and viruses • Supports autolytic debridement • Some evidence of wound odor reduction 	<ul style="list-style-type: none"> • Comes in many forms • Look for leptospermum species • Avoid in patients with allergies to honey
Topical Antibiotics	<ul style="list-style-type: none"> • Kills susceptible bacteria 	<ul style="list-style-type: none"> • Some are OTC and some are Rx • Increasing bacterial resistance
Oral Antibiotics	<ul style="list-style-type: none"> • Kills susceptible bacteria 	<ul style="list-style-type: none"> • Provider must order Rx • Increasing bacterial resistance • Often ordered empirically in the hospice setting
Sodium Hypochlorite	<ul style="list-style-type: none"> • Broad spectrum antimicrobial action • Facilitates chemical debridement • Reduces wound odor 	<ul style="list-style-type: none"> • Conflicting studies about cytotoxicity • May cause burning/stinging • Typically used for 14 days or less

3

SKIN BREAKDOWN PREVENTION



SKIN BREAKDOWN PREVENTION



...to skin breakdown!

ASSESSMENT

Head to toe skin assessment	<ul style="list-style-type: none">• On admit• Every 2 weeks at minimum for PPS 40 and above• Weekly at minimum for PPS 30 and less
Contributing factor assessment	<ul style="list-style-type: none">• Disease process(es)• Nutritional status• Mobility status• Cognitive status• Incontinence
Skin breakdown risk assessment	<ul style="list-style-type: none">• Braden• Hunters Hill Marie Curie Centre - Pressure sore risk assessment (for palliative patients)
Pain	<ul style="list-style-type: none">• Routine assessment and management

MOBILITY

Chair cushion

- When sitting in WC or chair (NOT donut cushions)
- Shift position every 15-60 minutes

HOB

- As low as medically necessary or tolerable

Sheets

- Silk like sheets
- Use transfer/turning sheet
- Limit number of sheets/incontinence pads

Activity

- Mobility devices to support independence, activity and mobility



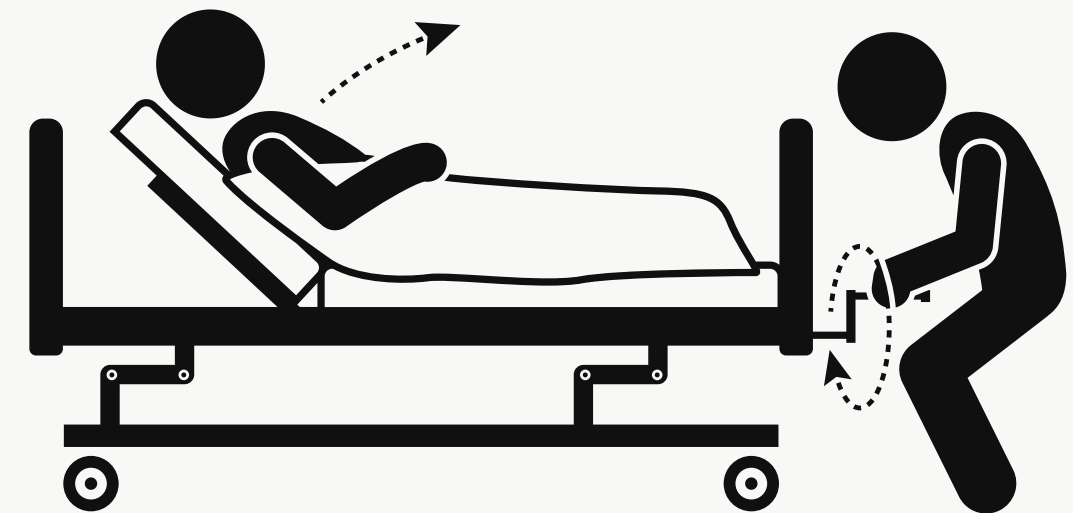
MOBILITY

Turn and reposition

- Q2 hours for standard mattress
- Q4 hours for pressure-redistributing mattress
- Avoid placement directly on trochanter
- Appropriate support surface for bed/condition/weight
- Avoid placement on medical devices
- Lifts as appropriate

Heels/Feet

- Pillow longitudinally under calves
- Heel protection boots (NOT moon boots)
- Foot Support



INCONTINENCE

Moisture

- Prompt incontinence care
- Barrier cream/ointments/paste
- pH balanced cleanser
- Containment devices (as appropriate)
 - Foley
 - Fecal pouch
 - Purewick
 - Condom cath




SKIN

Skin

- Moisturize skin 1-2x daily
- Pad bony prominences
- Eliminate friction and shear


Nutrition

- Small, frequent meals
- High protein
- Supplements

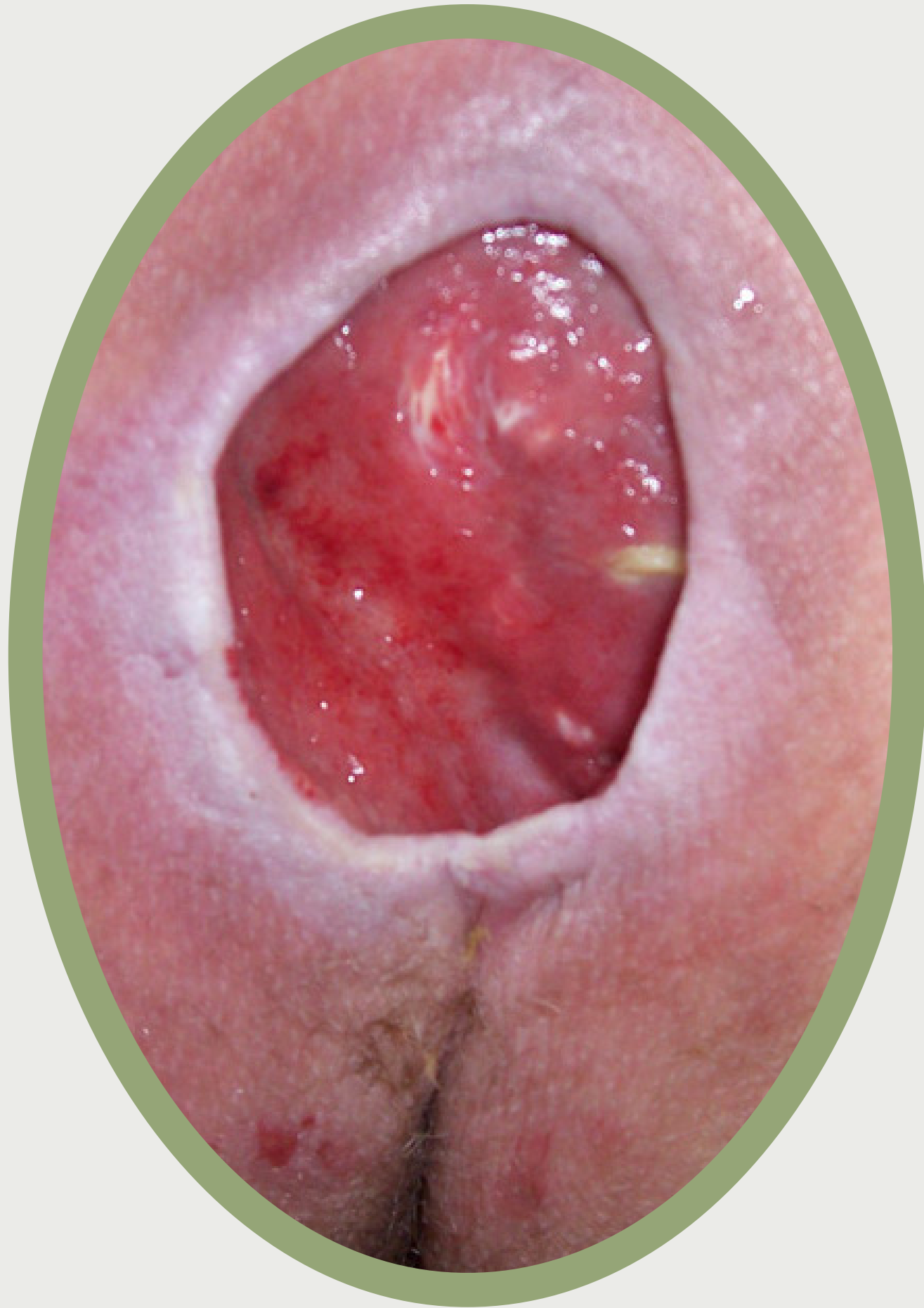


4

CASE STUDIES



CASE STUDY #1



84 y/o male patient on service for CHF with an ejection fraction of 20%.

Comorbidities include HTN, hyperlipidemia, atrial fibrillation. Has developed the wound in the graphic.

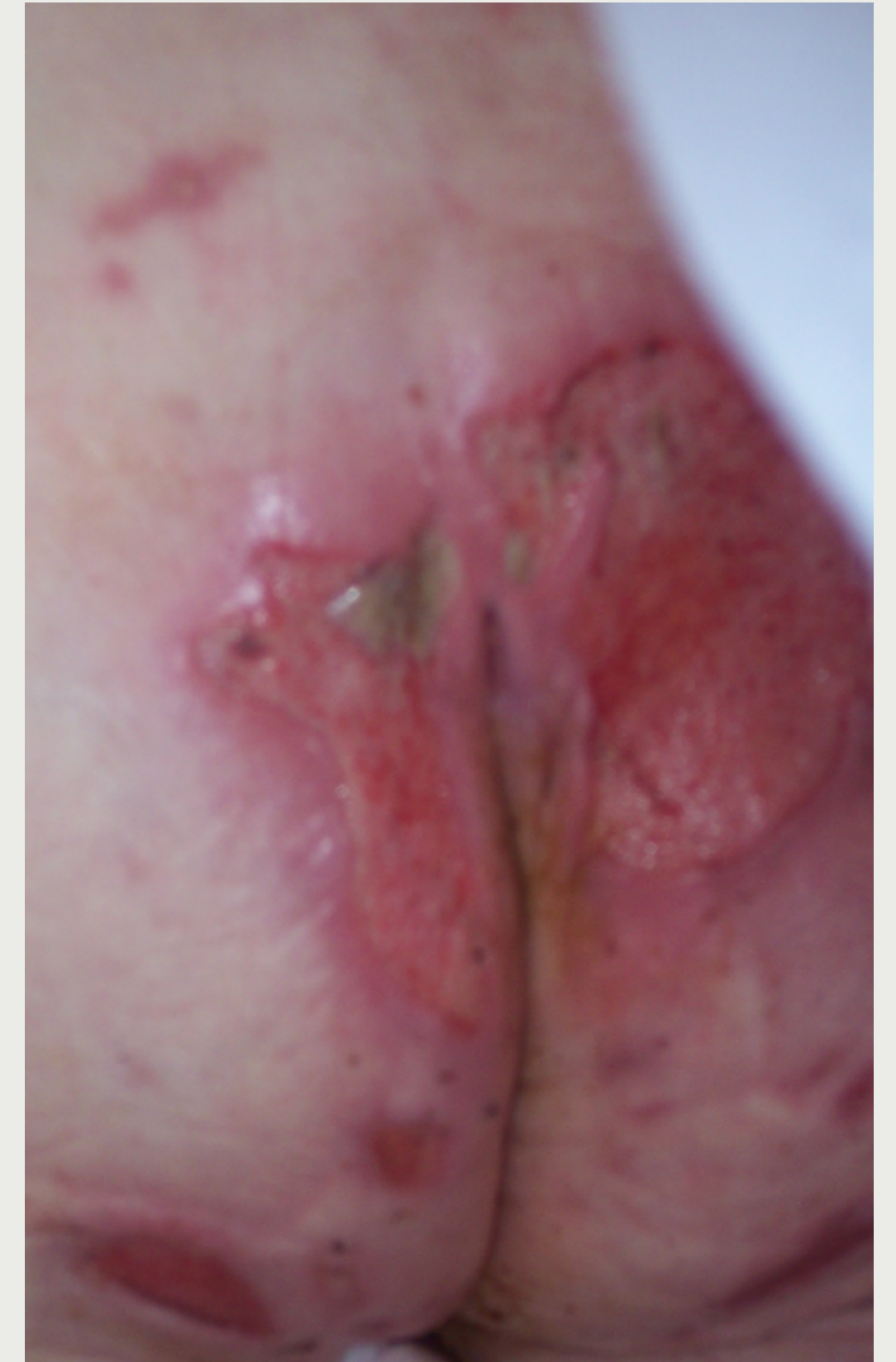- What kind of wound is this?
- How would you document what you see?
- Any care suggestions?

CASE STUDY #2

97 y/o female on service with Alzheimer's. She lives in a memory care unit, has a PPS of 30%, and is incontinent bowel/bladder. She has a BMI of 16. She uses poise pads in her underwear but often has leaks. Her skin is beginning to look irritated and you are worried it may be starting to break down.

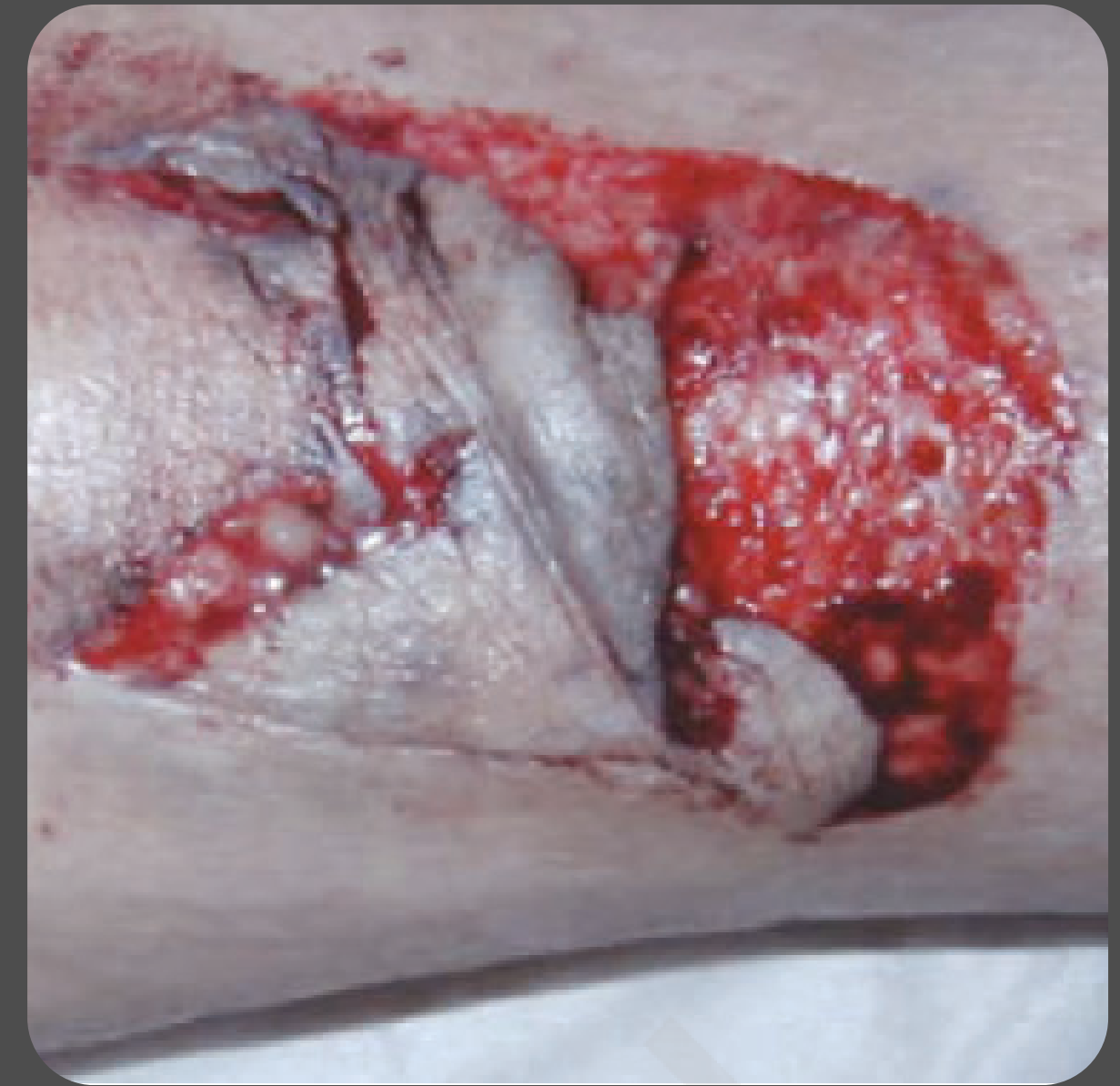Her husband had a horrible sore on his sacrum and the family is really worried about their mother developing one as well.

- What might lead to skin breakdown?
- What are some interventions you might consider?
- What kinds of things might you discuss with the facility?



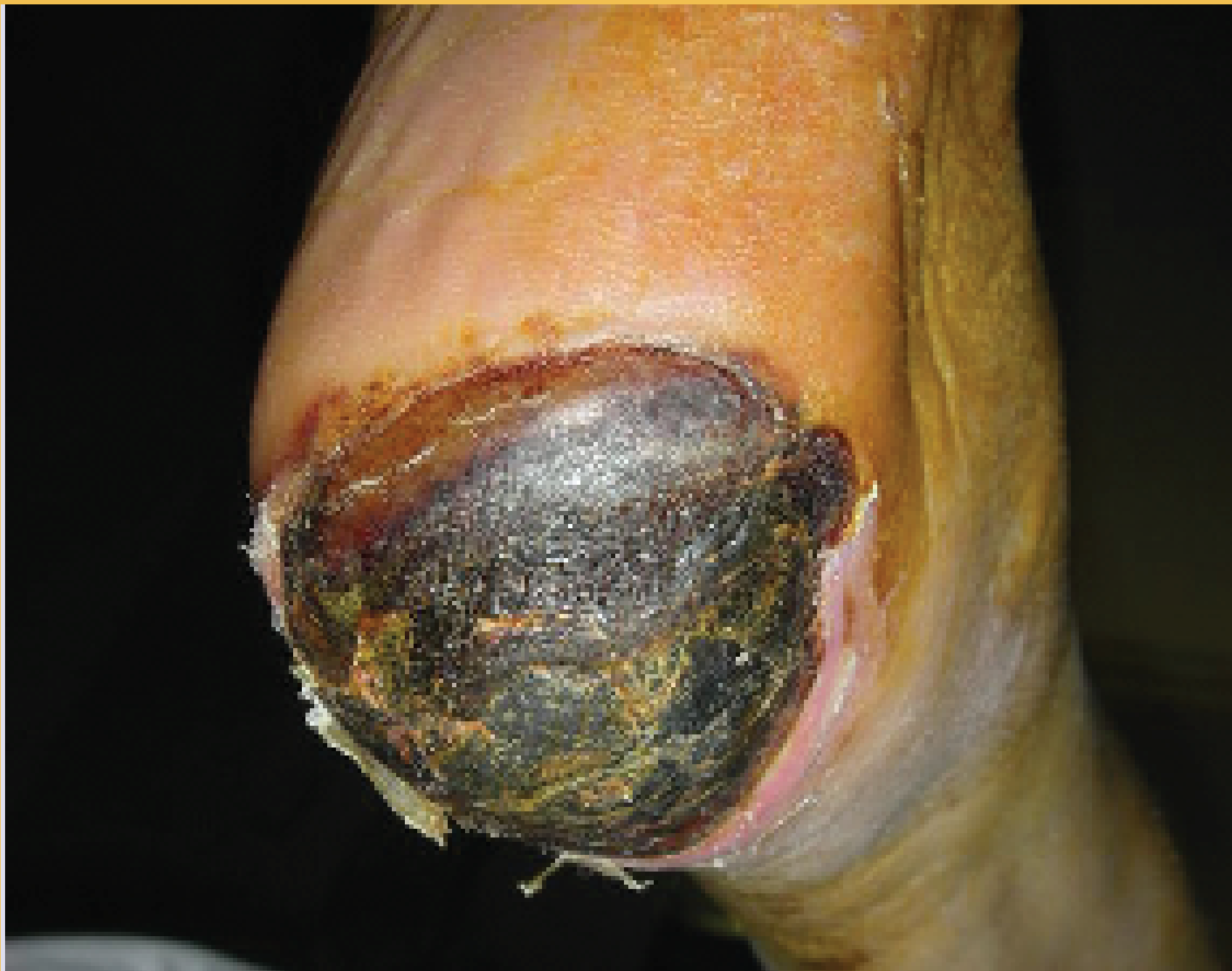89 y/o female with Alzheimer's sustained a fall and hit her arm:

- What kind of injury is this?
- How could we prevent this in the future?
- What education might you provide for her caregivers?



CASE STUDY #3

CASE STUDY #4



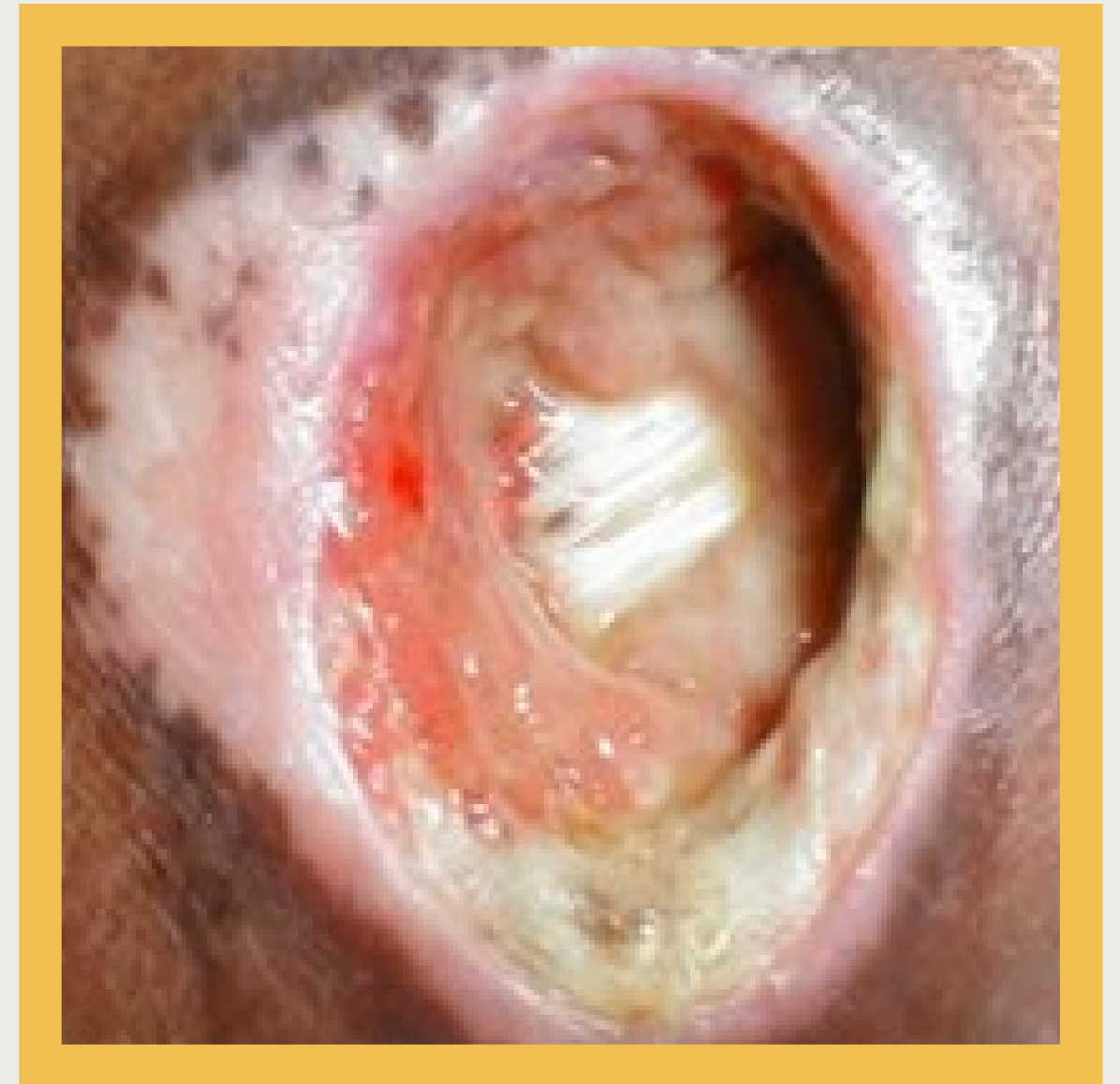84 y/o patient presents with the wound in the image to their left heel. The patient is bedbound, and has advanced Alzheimer's.

- What type of wound is this?
- What caused it?
- What should we do about it?
- How should this be prevented?
- What will you document?

CASE STUDY #5

96 y/o patient presents with the pressure ulcer in the image. The patient is bedbound from Parkinson's. There is a moderate amount of drainage and the wound has a faint odor after removing the dressing. The wound is chronic, and has not changed in the last 6 weeks.

- What kind of wound is this?
- How might you document this wound?
- What treatments might you recommend?





toccara.jule@deltacarerx.com

